

# Macular Hole

*R. Spaide*

*Vitreous Retina Macula Consultants of  
New York, NY, USA*

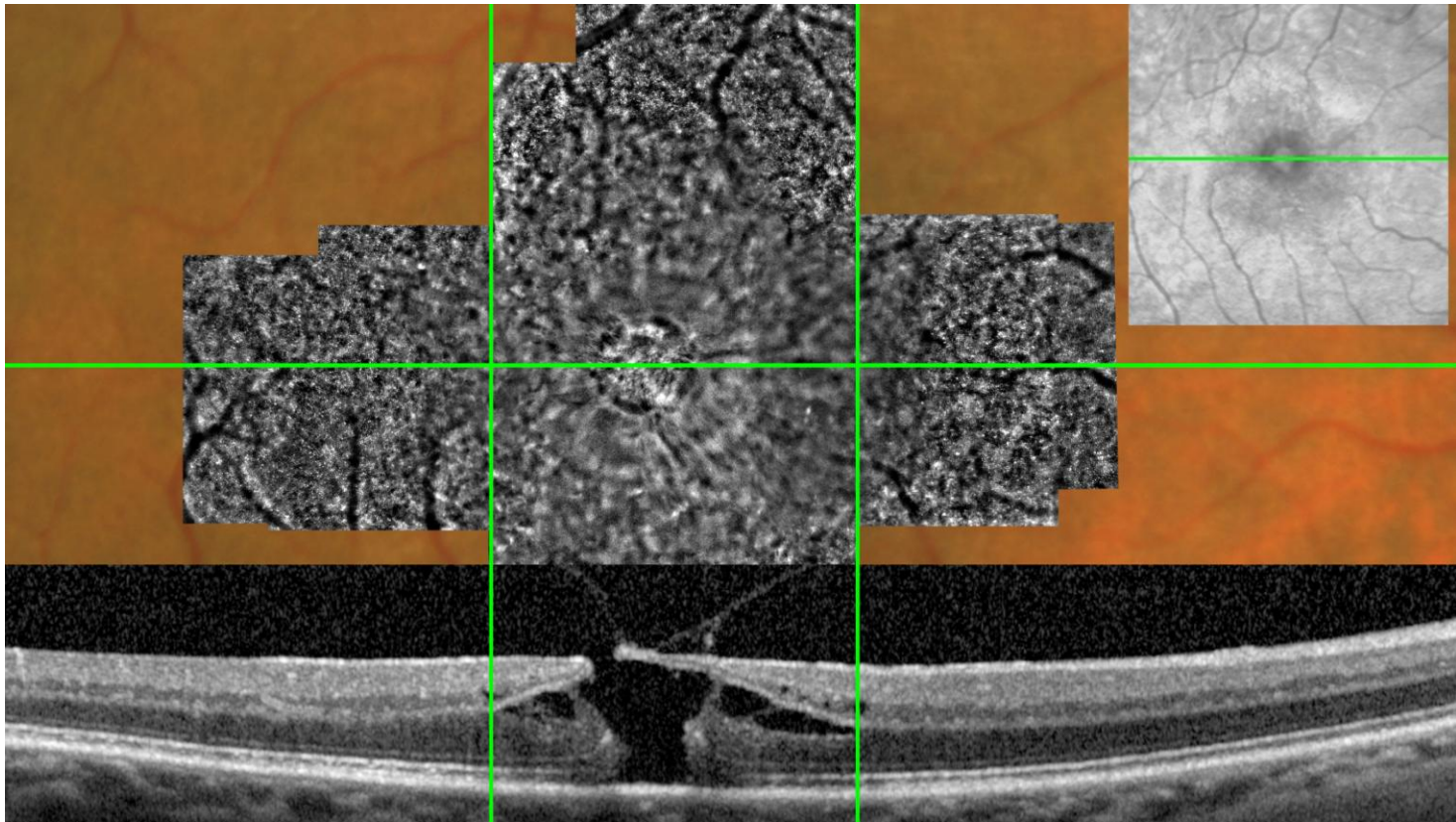


VITREOUS-RETINA-MACULA  
CONSULTANTS OF NEW YORK

# Multimodal examination

---

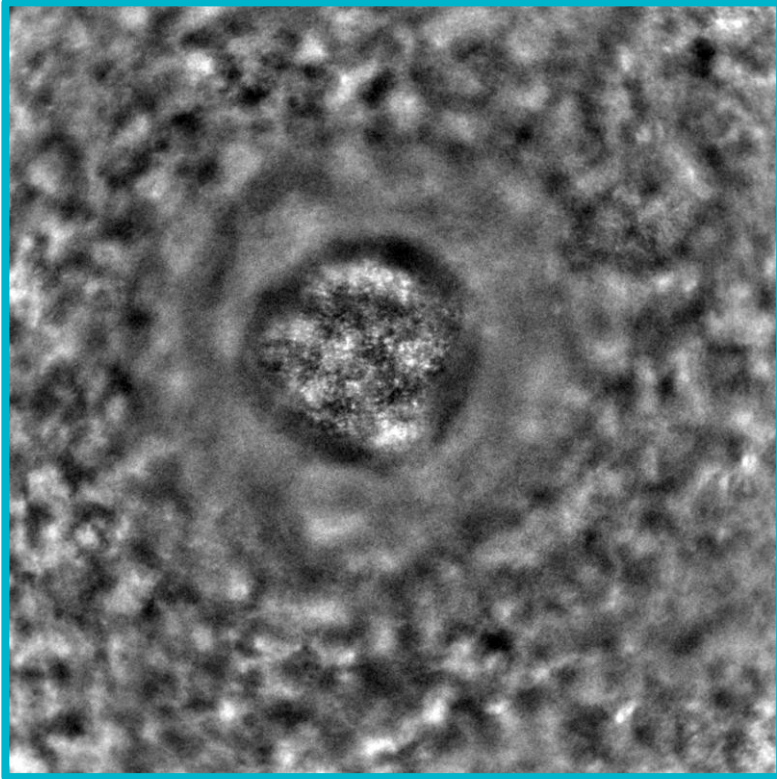
Male, 61 yrs old. Epiretinal membrane with pucker and a full thickness macular hole. Images two weeks pre-operation.




# Pre- and post operation

---

Images two weeks before and after operation.



Hyper reflective dots are visible inside the macular hole before operation.



The edema around the hole decreases after operation and cones are again visible: this is also thanks to the change of orientation of the cones.

# Conclusion

---

- Adaptive optics allows to image the structures inside a macular hole with microscopic resolution.
- Outside the macular hole, cones appear visible again when the macular edema is reduced, and when their orientation is back to normal.

