imagine eyes

Tracking diseases at cellular and microvascular levels

rtx1™ ADAPTIVE OPTICS RETINAL CAMERA



WORLD'S FIRST IMAGING MICROSCOPE FOR THE LIVING RETINA

- Non-invasive **cellular** and **microvascular** retinal imaging
- Wide-ranging applications in **ophthalmic** and **systemic** diseases

Cellular resolution

Comparison with a scanning laser ophthalmoscope (SLO)



Resolution 15-20 µm

Resolution 3-4 µm

Visual cells are visible

imagine eyes

Cellular live image

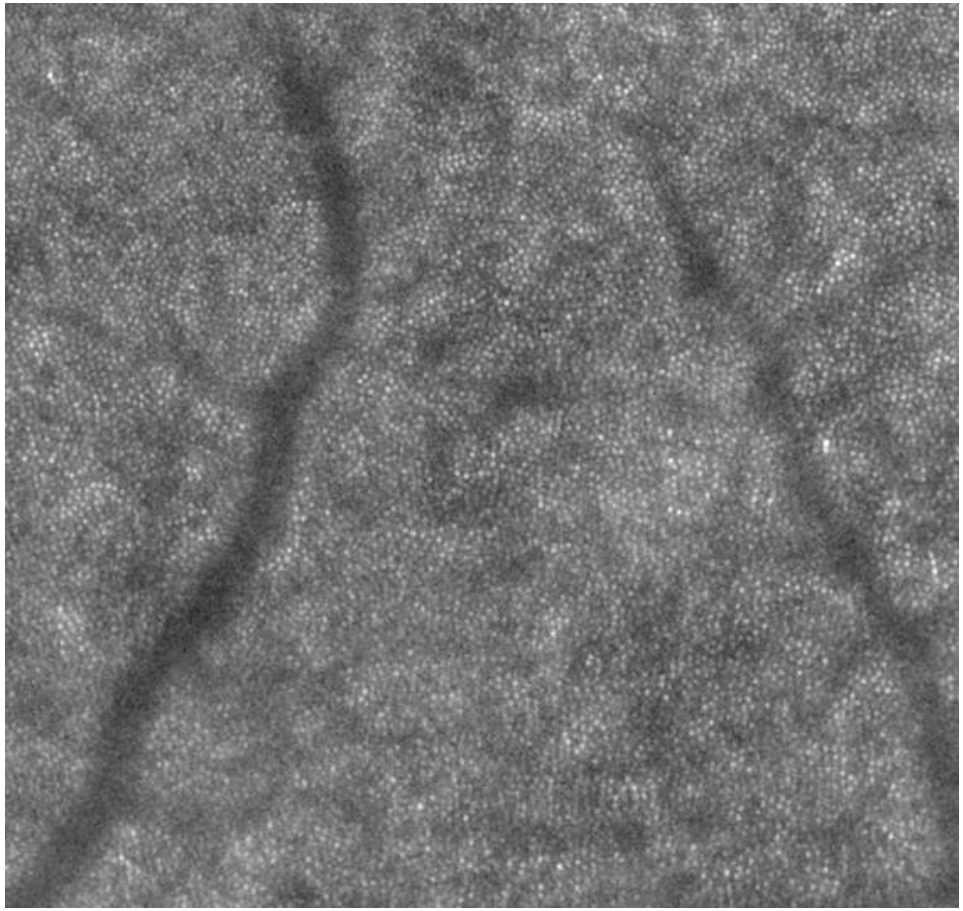

imagine eyes

Cellular processed image

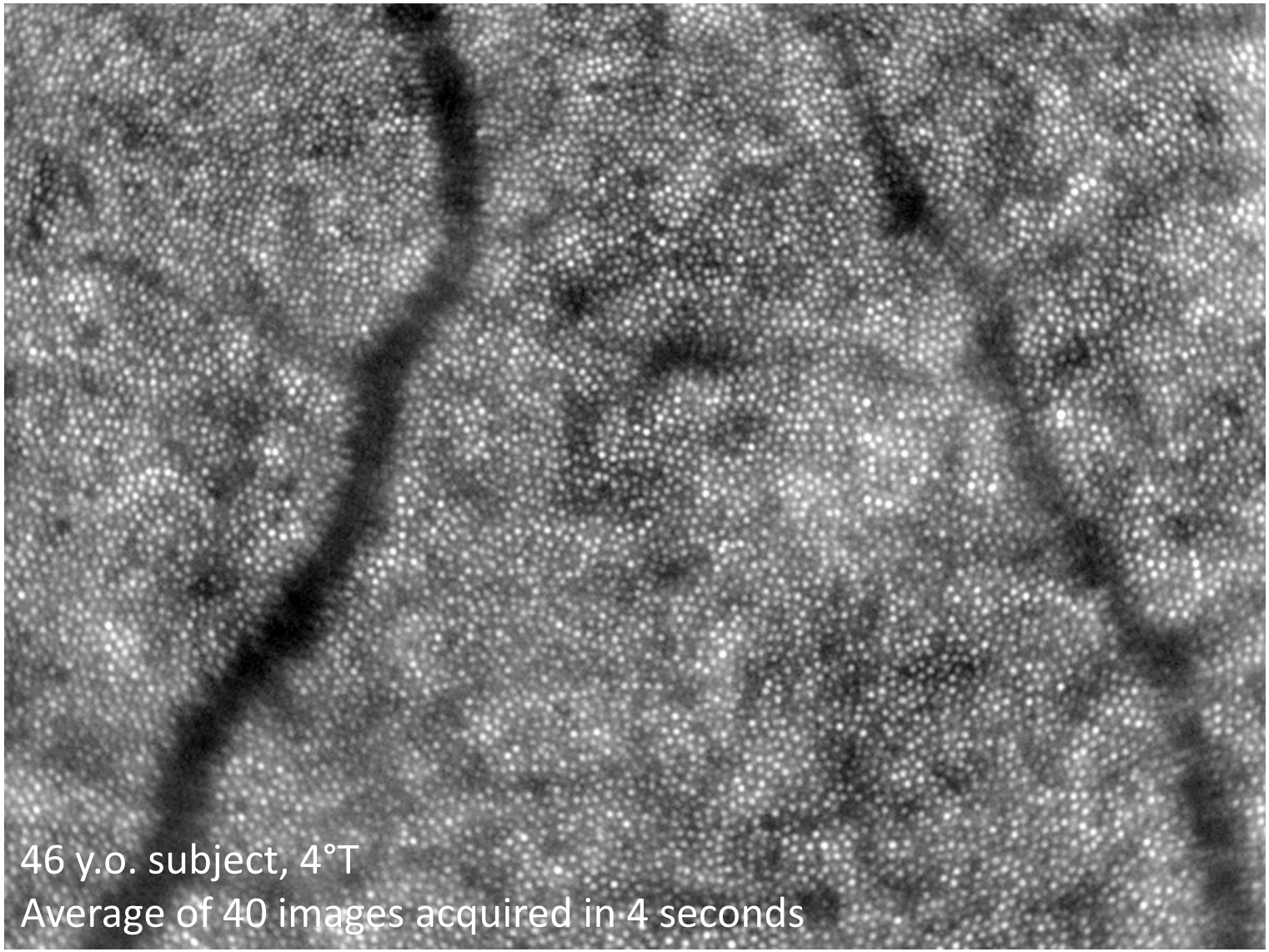

imagine eyes

Microvascular resolution

Comparison with a conventional numeric retinal camera

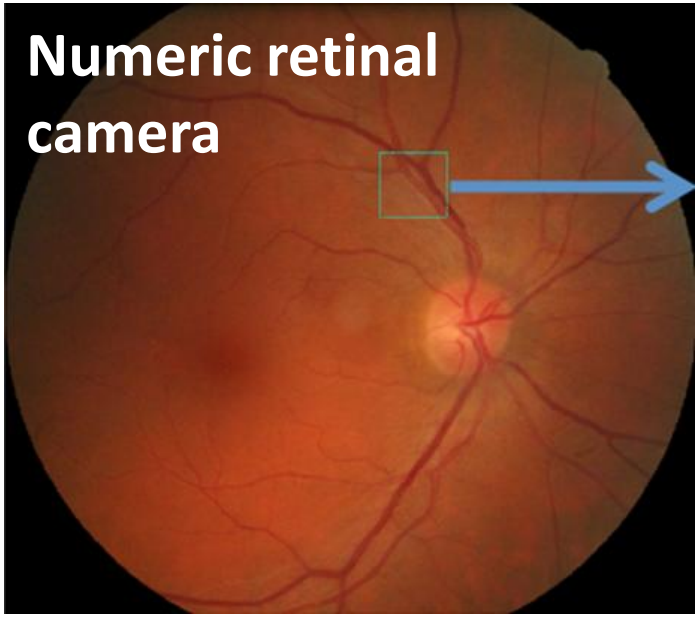

Resolution 15-20 µm

Resolution 3-4 µm

Small artery structures and walls are visible

imagine eyes

Microvascular live image

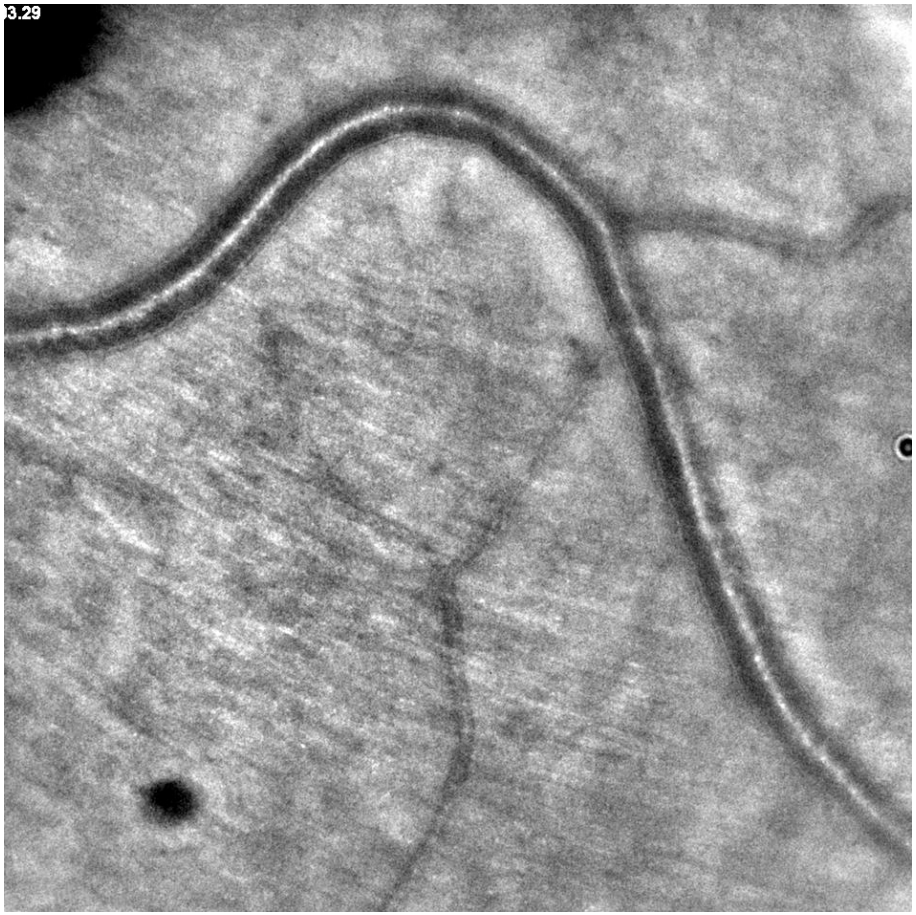

imagine eyes

Microvascular processed image

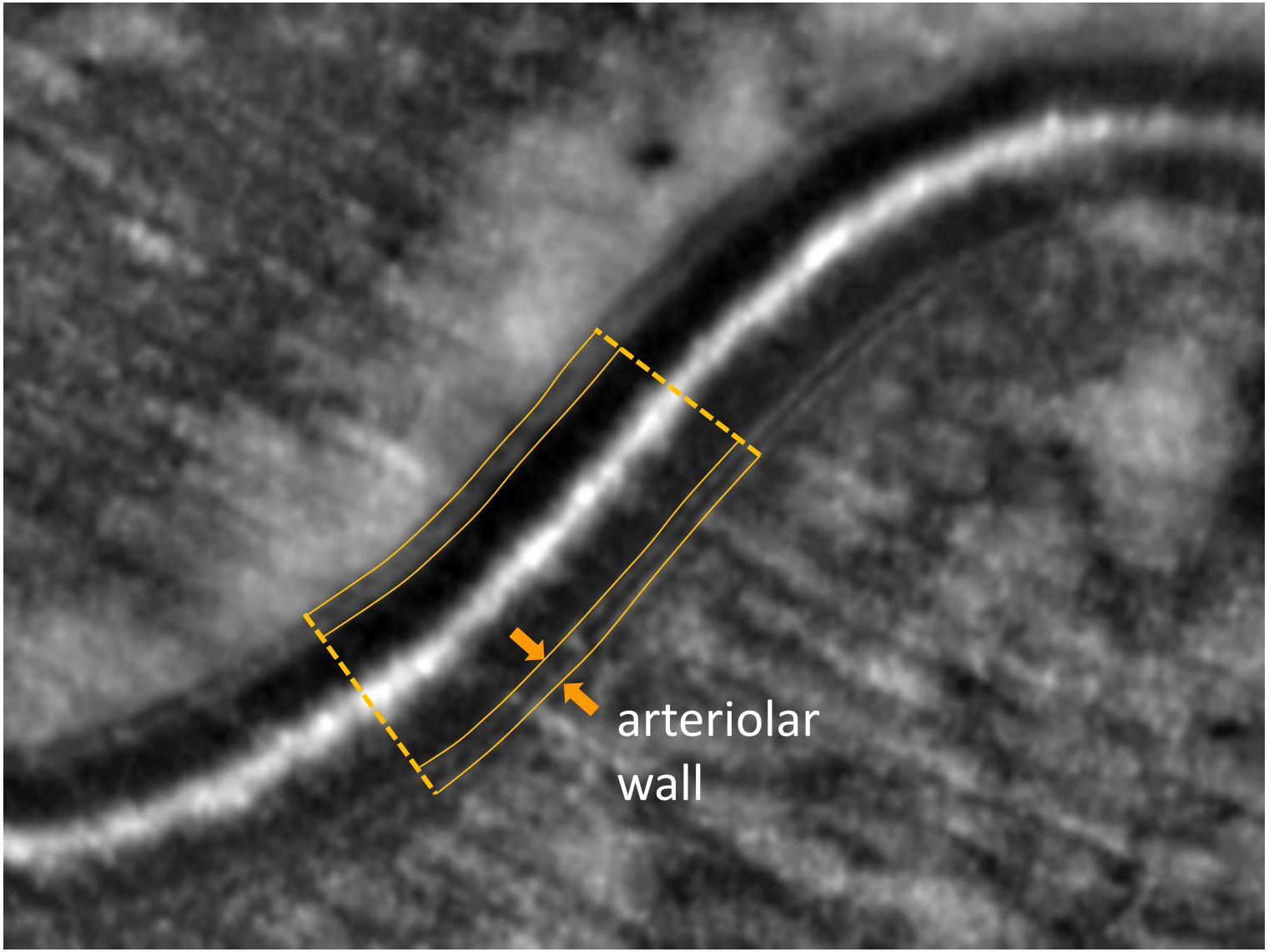

imagine eyes

Optic nerve imaging

Pores in the lamina cribrosa are visible

imagine eyes

Optic nerve live image

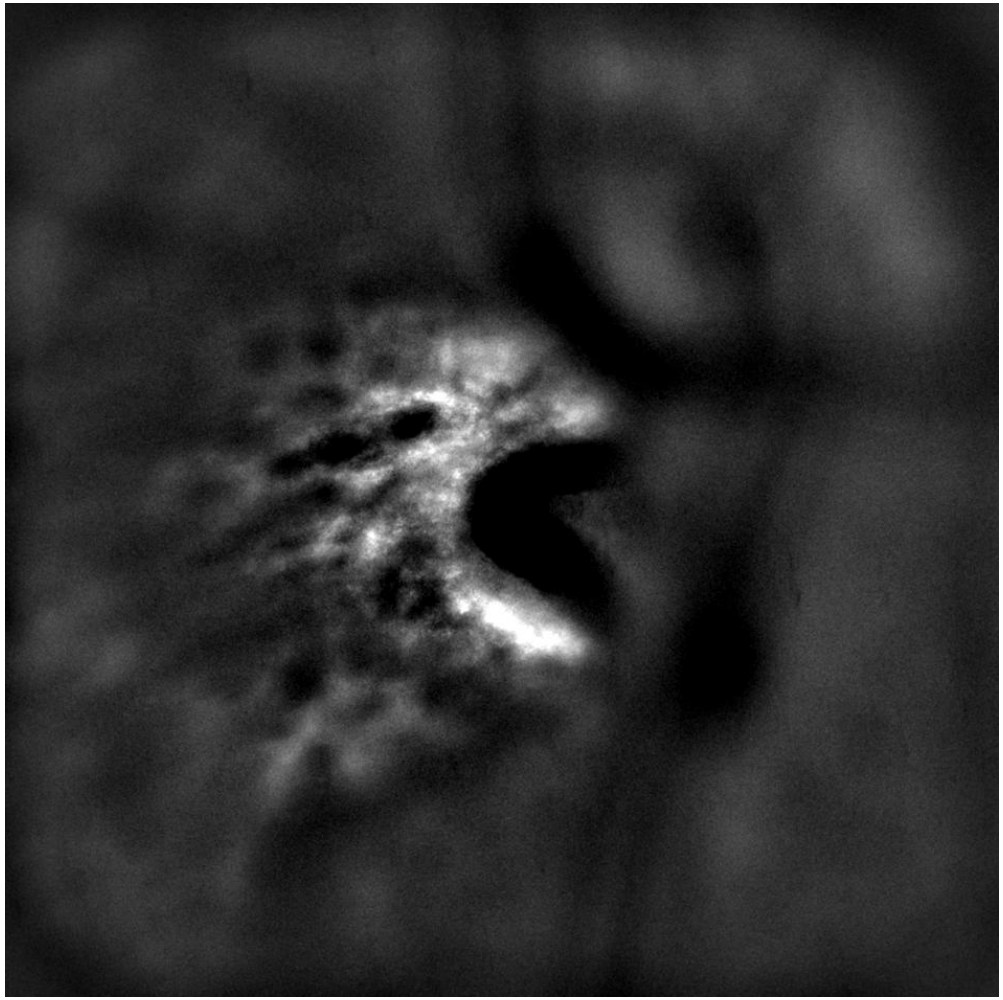

imagine eyes

Retinal microscopy achieved through **fast** and **comfortable** examinations

Resolving power	250 line pairs /mm
Illumination wavelength	850 nm
Image field	4 deg x 4 deg
Exposure time	< 10 ms
Total acquisition time	4 s

- The rtx1 is an approved medical device in the European Union (CE mark), in Japan (Shonin) and in Australia (ARTC approval).
- In the USA, the rtx1 has not received FDA clearance. It is an investigational device and requires Institutional Review Board (IRB) oversight for use in any research application

imagine eyes



SOFTWARE FOR THE rtx1

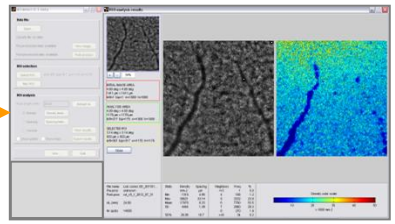

AOdetect™-mosaic

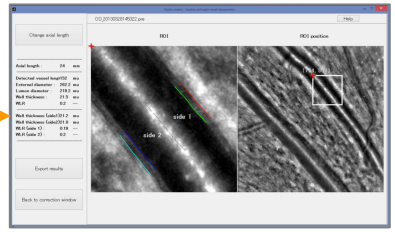

AOdetect™-artery

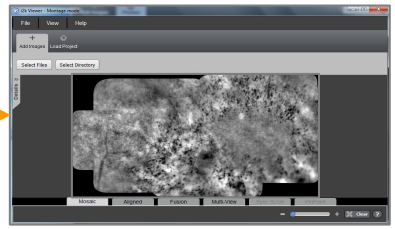

i2k Retina®

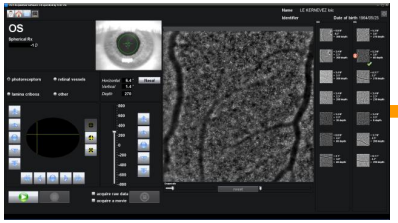

AOimage™

AOimage™
Adaptive optics imaging **made easy**

- User-friendly interface
- Network-compatible database
- Fully automated AO operation
- Easy localization, focussing and capture
- Selectable fixation target pattern
- Fast multithread image processing
- Export to multiple image formats including PNG and DICOM
- Interface compatible with dim light environment
- Remote access viewer

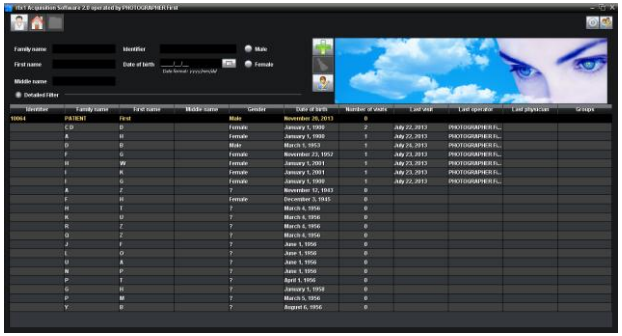

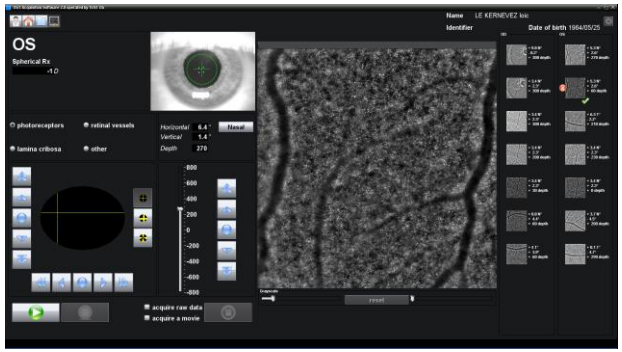

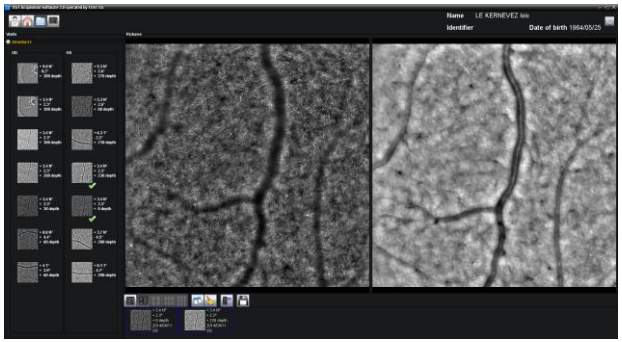

imagine eyes

AOdetect™-mosaic

Cone photoreceptor mosaic analysis

- Region-of-interest selection
- Cone detection (extrafoveolar)
- Cell density maps
- Inter-cell spacing maps
- Pleomorphism maps
- Descriptive cell statistics
- Export to text, excel and graphic files

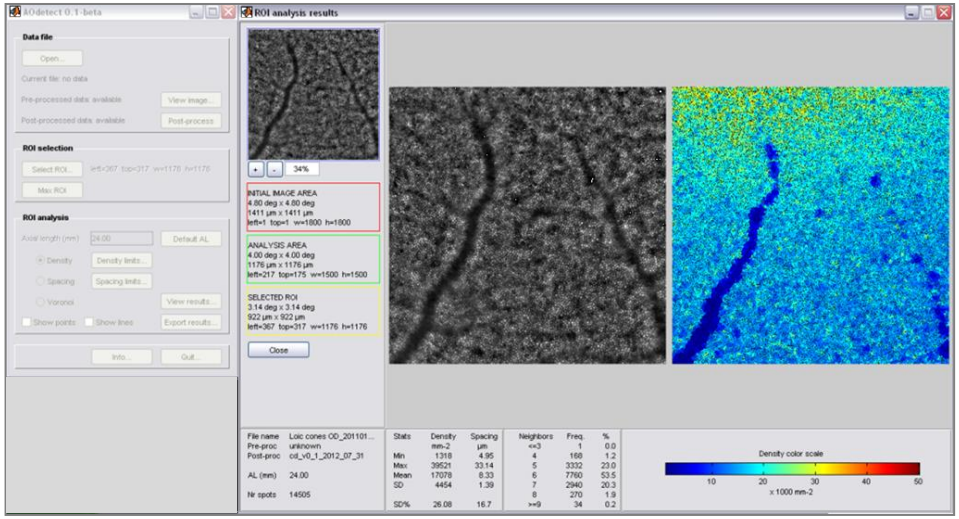

Stats	Density mm-2	Spacing µm	Neighbors	Freq.	%
			<=3	0	0.0
Min	11058	6.55	4	3	0.5
Max	28010	10.91	5	144	23.0
Mean	18055	8.22	6	338	54.1
SD	2358	0.66	7	127	20.3
			8	13	2.1
SD%	13.06	8.0	>=9	0	0.0

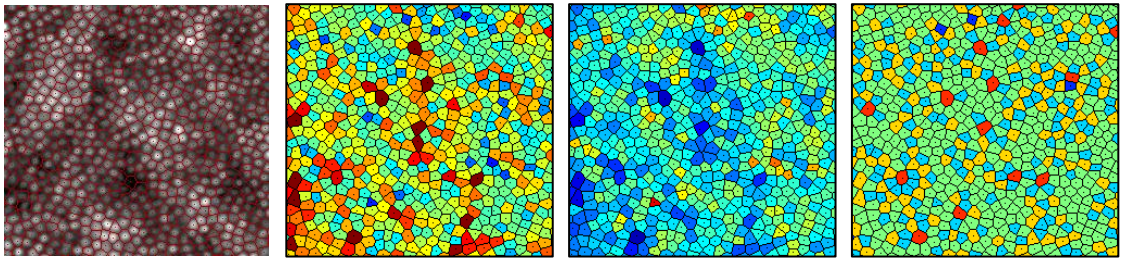

imagine eyes

Aodetect-mosaic is an investigational software application, for research use only

AOdetect™- artery
Arteriolar microstructure analysis

Software under development

- Arteriolar wall segmentation
- Internal (lumen) and external diameter measurements
- Wall thickness and wall-to-lumen ratio assessments

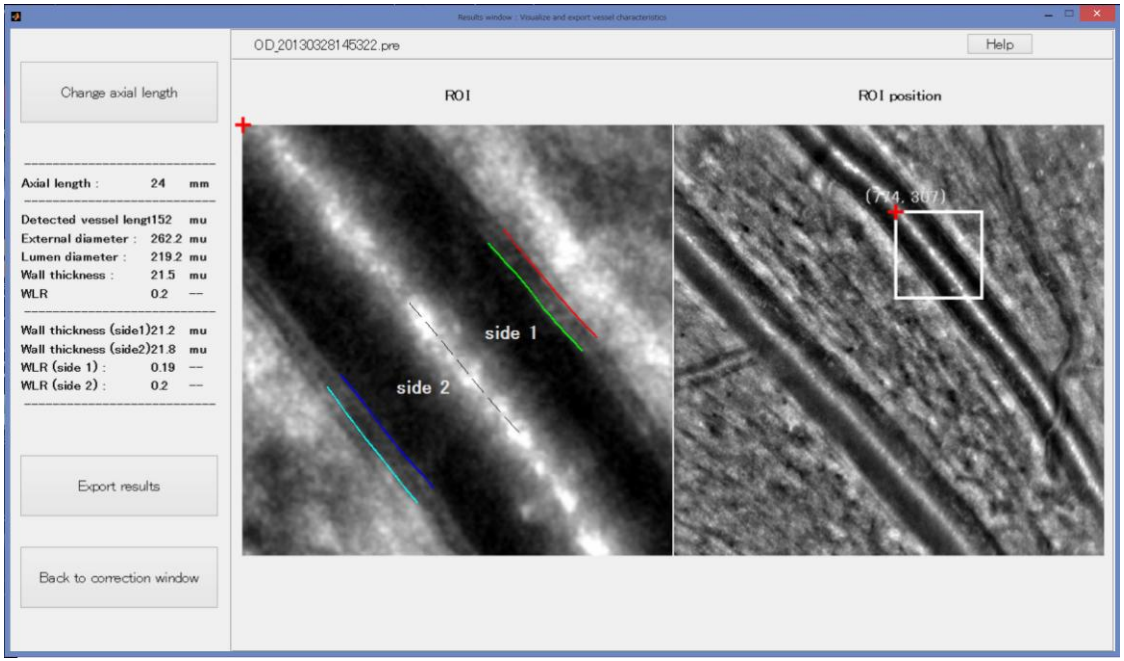

imagine eyes

Aodetect-artery is an investigational software application, for research use only

i2k Retina®
Automatic multi-image stitching

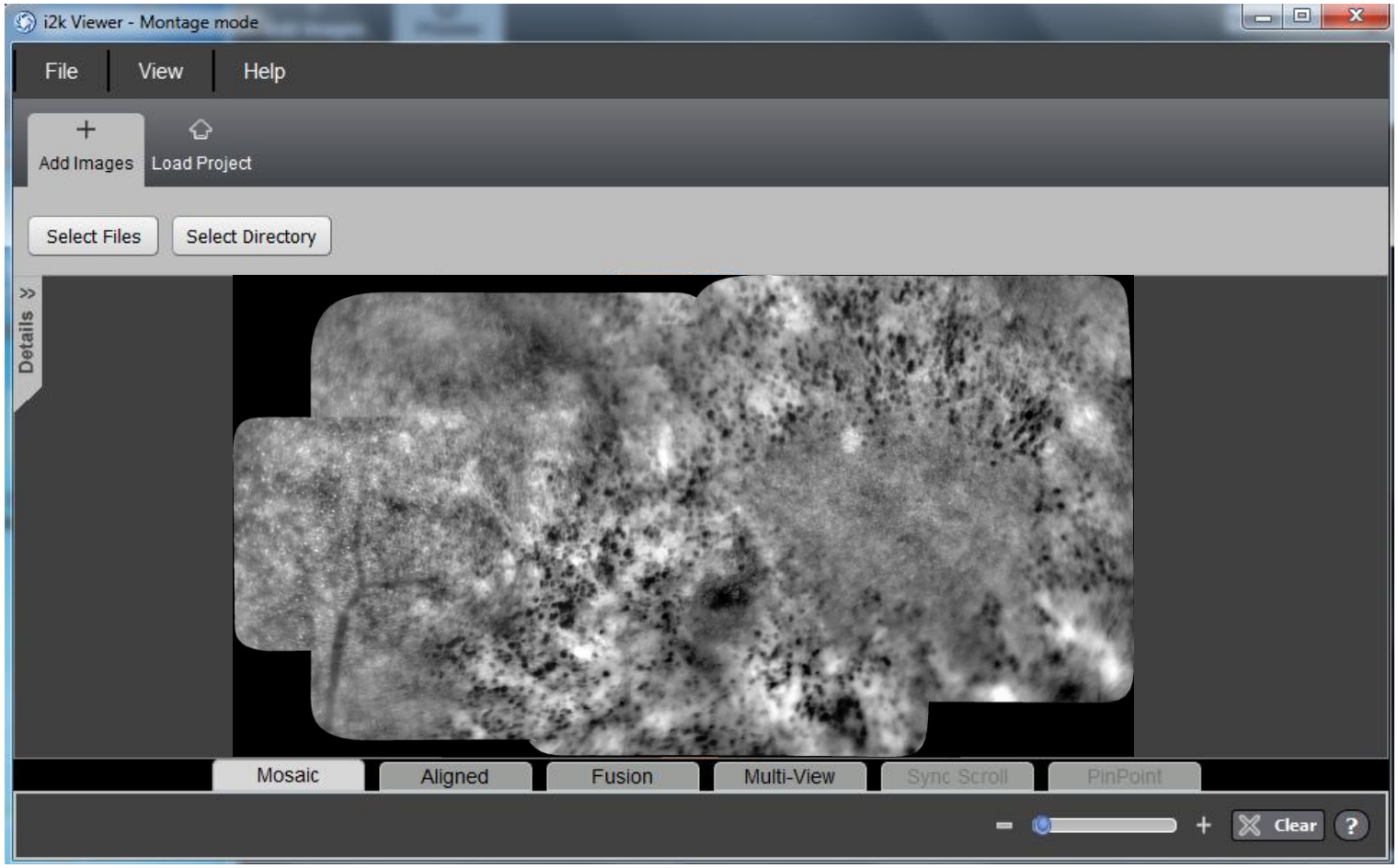

imagine eyes

i2k Retina® is a registered trademark of DualAlign™LLC

rtx1 APPLICATIONS

- Inherited retinal diseases
- Dry AMD
- Vitroretinal surgery
- Drug toxicity
- Glaucoma research
- Diabetes
- Vascular inflammation
- Arterial hypertension

Inherited retinal degenerative diseases

- The rtx1 reveals previously unseen microscopic structures including **cone photorecetor cells**
- It provides highly-sensitive **biomarkers** for tracking cell loss:
  - Cone density
  - Inter-cone spacing
  - Cone pleomorphism

Usher syndrome

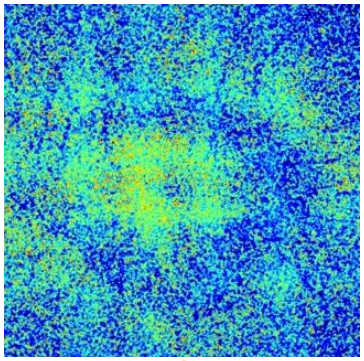

Healthy retina



Cone density

Autosomal dominant optic atrophy (ADOA)

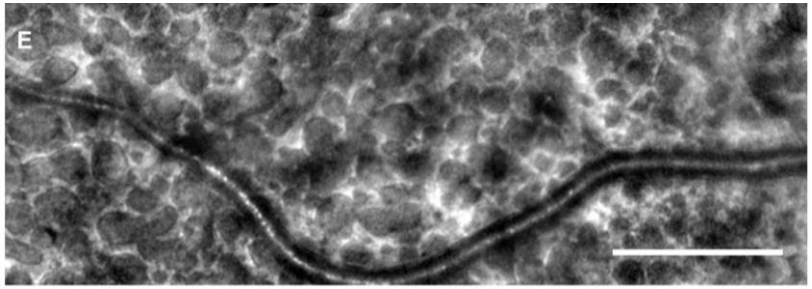

Microcystic macular edema
visible in the AO image

Clinical Study
High-Resolution *En Face* Images of Microcystic Macular Edema in Patients with Autosomal Dominant Optic Atrophy
Kiyoko Gocho,[1] Sachiko Kikuchi,[1] Takenori Kabuto,[1] Shuhei Kameya,[1] Kei Shinoda,[2] Atsushi Mizota,[2] Kunihiko Yamaki,[1] and Hiroshi Takahashi[3]

CASE REPORT
Analysis of macular cone photoreceptors in a case of occult macular dystrophy
Naoki Tojo
Tomoko Nakamura
Chiharu Fuchizawa
Toshihiko Oiwake
Atsushi Hayashi

CASE SERIES
photoreceptors in the macula of patients with retinitis pigmentosa
Naoki Tojo
Tomoko Nakamura
Chiharu Fuchizawa
Toshihiko Oiwake
Atsushi Hayashi

imagine eyes

Usher images: courtesy of Pennesi et al., Oregon Health & Science University, Portland, USA
ADOA image: courtesy of Gocho , Kameya et al., Nippon Medical School Hokusoh Hospital, Chiba, Japan

Adaptive optics imaging in

RETINITIS PIGMENTOSA

Retinitis pigmentosa (RP)

Healthy subject

38 years



1°T 2°T 4,5°T

RP patient

39 years

VA : 20/20



100 µm

RPE cells

Images : courtesy K. Gocho-Nakashima & O. Roche, Necker Hospital, Paris

imagine eyes

右眼

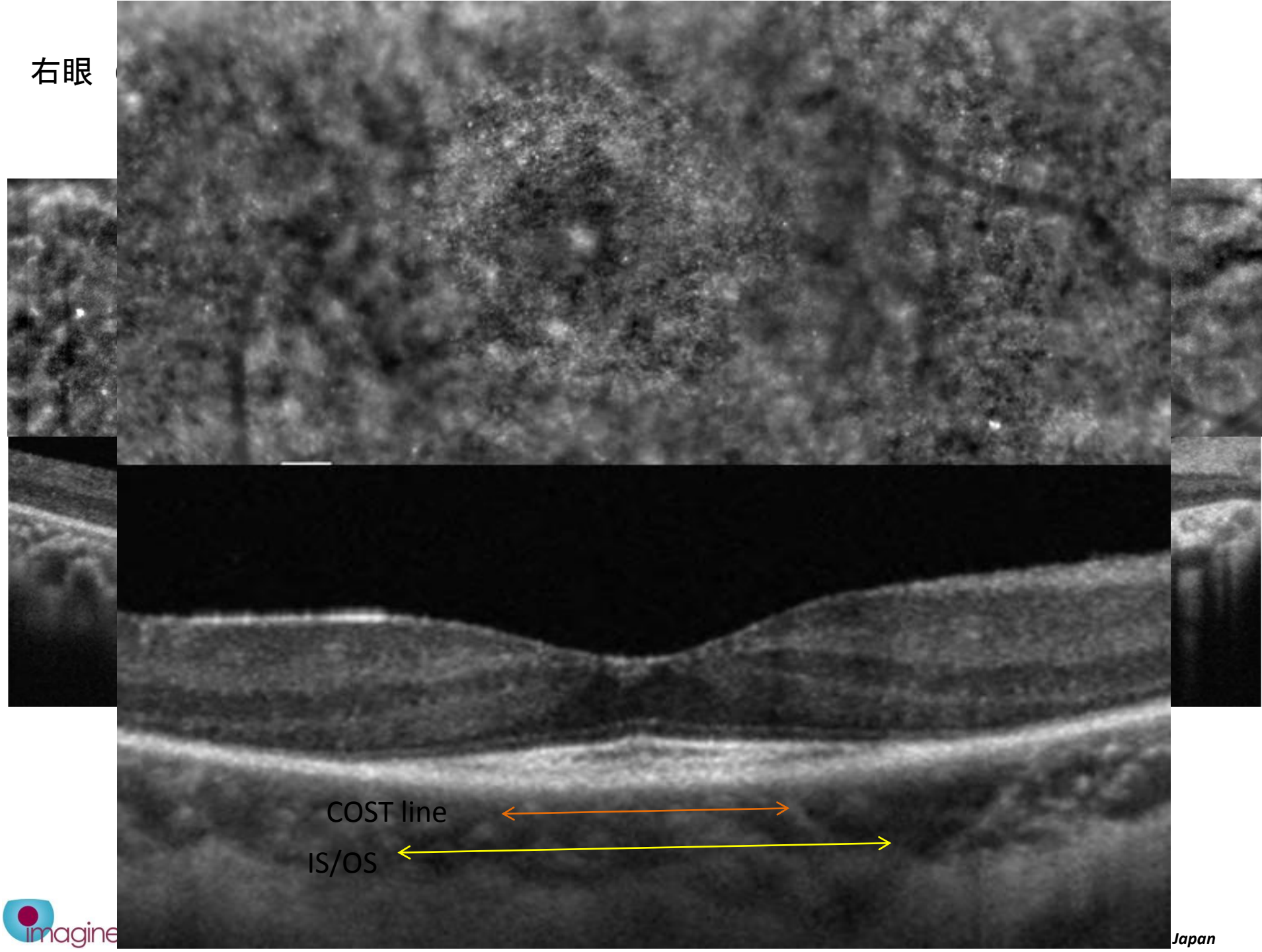

RP2_32-0891-5

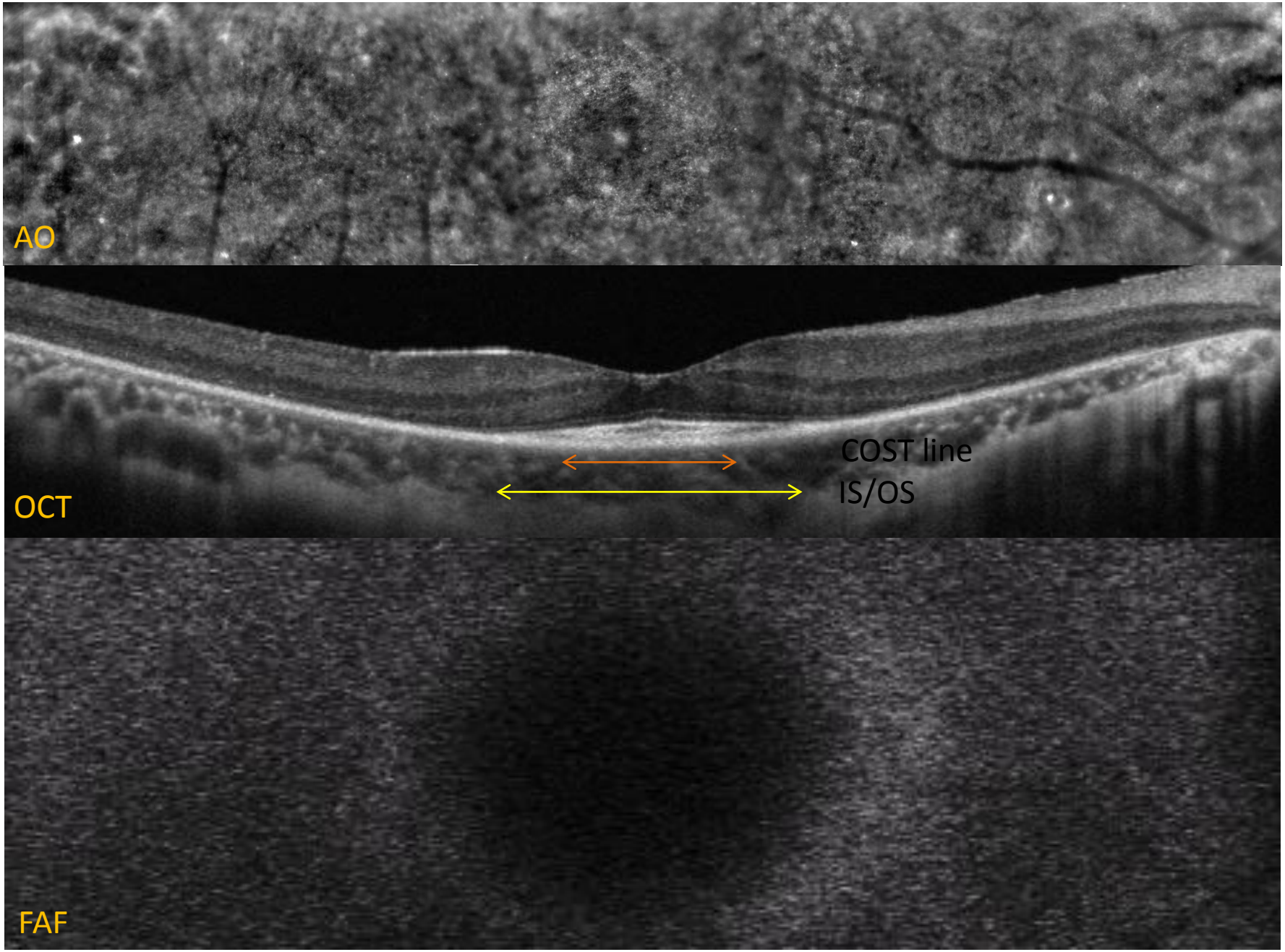

Courtesy A. Hayashi, Toyama University, Japan

Adaptive optics imaging in

STARGARDT

Stargardt #1

16 year old female

OD VA =20/100 OS VA =20/80

Visual Field : OD central scotoma <10 °

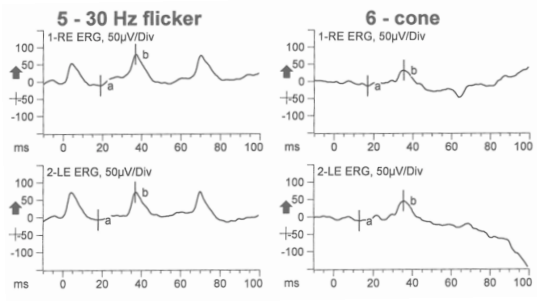

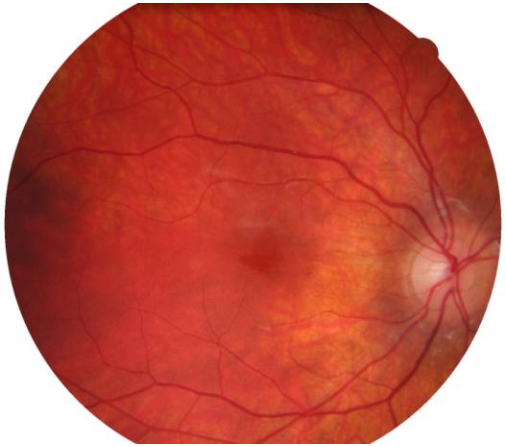

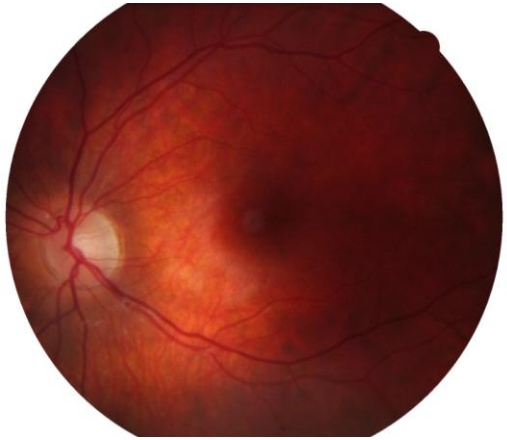

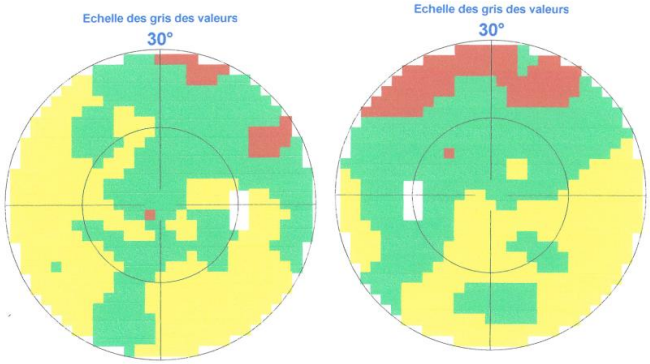

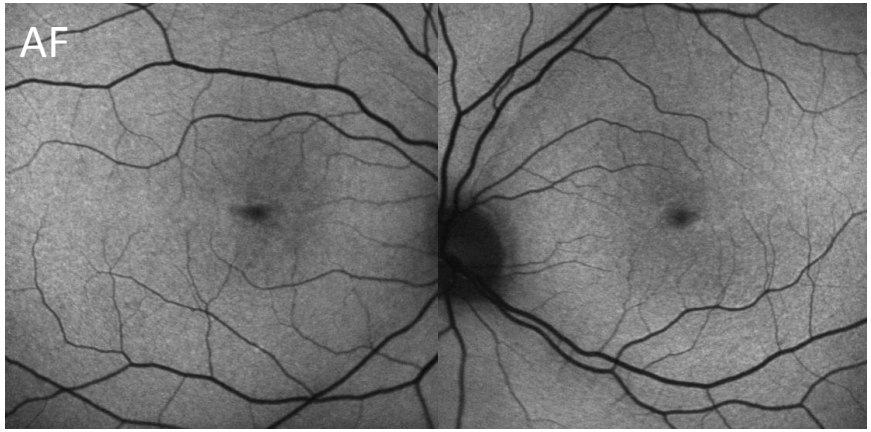

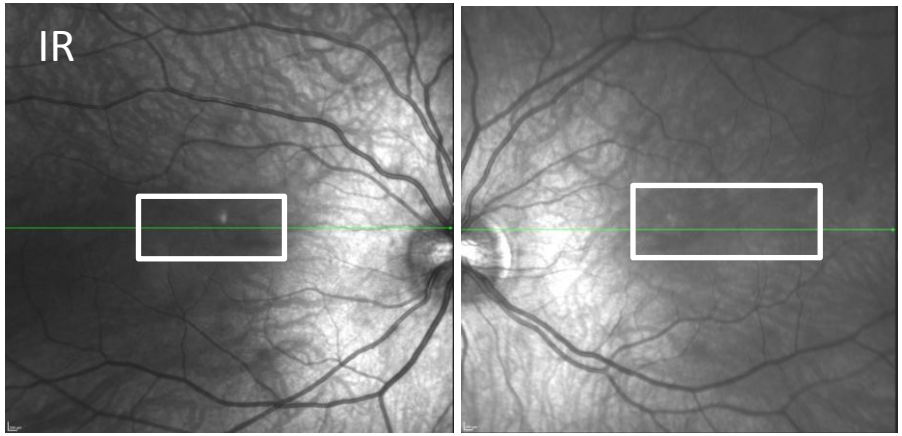

imagine eyes

Courtesy K. Gocho-Nakashima & M. Paques, Quinze-Vingts National Eye Hospital, Paris

Stargardt #1

16y F



imagine eyes

Courtesy K. Gocho-Nakashima & M. Paques, Quinze-Vingts National Eye Hospital, Paris

Stargard #1 vs. healthy retina

			Nr of cones	Spacing (µm)
Stargardt 16y F			58	24.4
Healthy			1472	4.8

imagine eyes

Analysis: courtesy K. Loquin & F. Rossant, ISEP, Paris, France

Stargardt #2

- 27 year old male
- OD VA = OS VA = 20/100
- Visual Field : central scotoma <10 deg

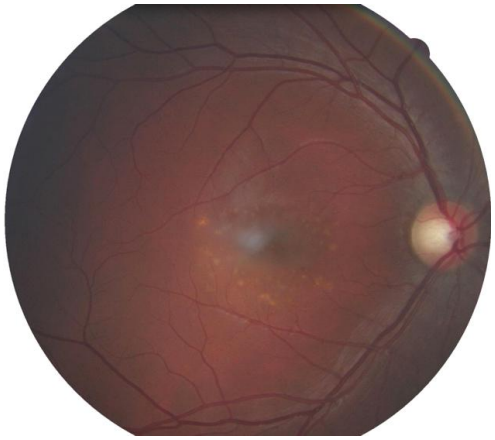

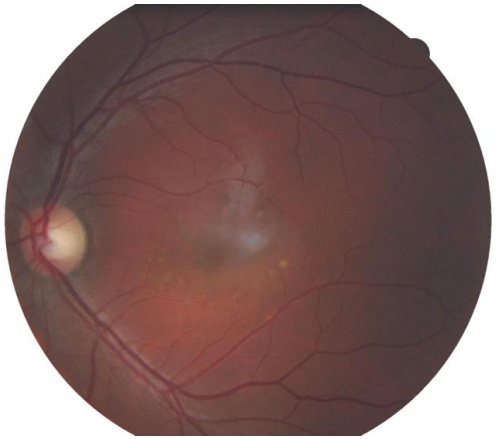

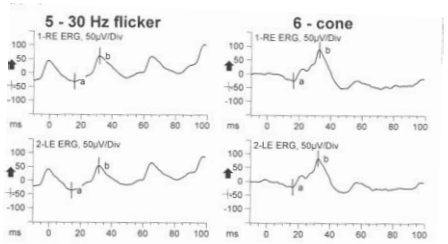

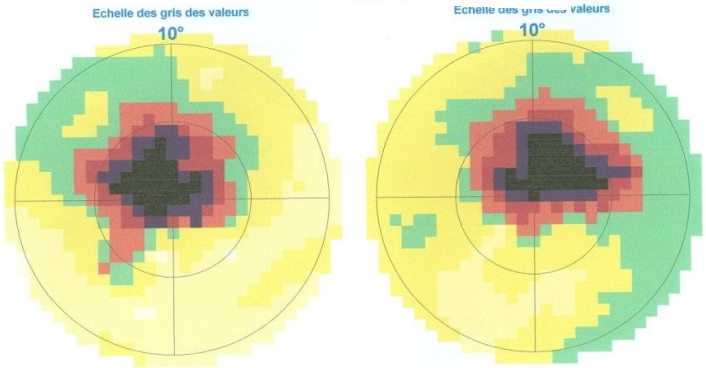

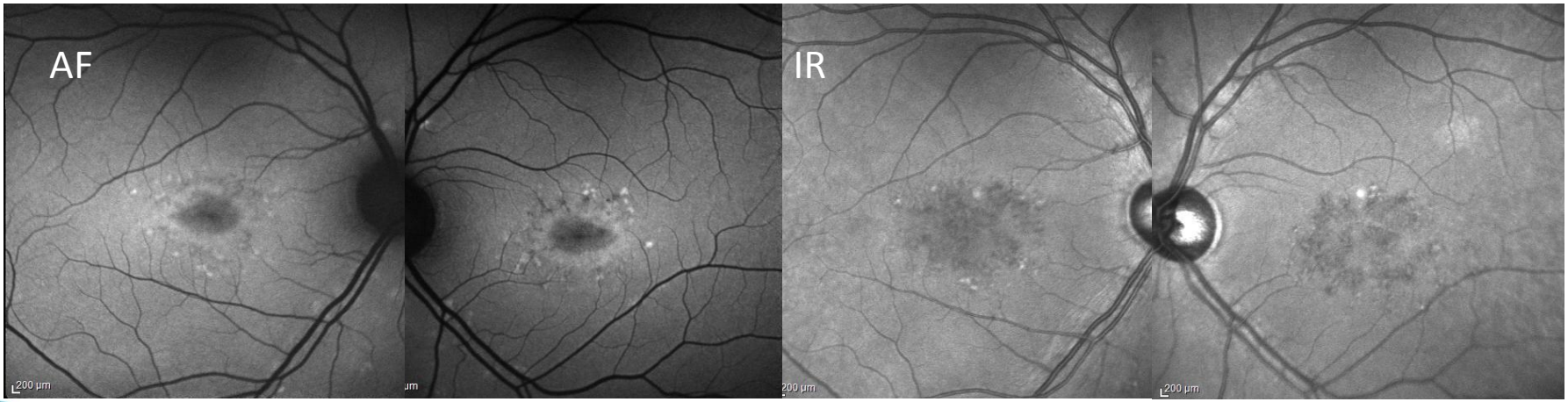

imagine eyes

Images : courtesy K. Nakashima & M. Paques, Quinze-Vingts National Eye Hospital, Paris

Stargardt #2 12-month follow-up

27y M

T0

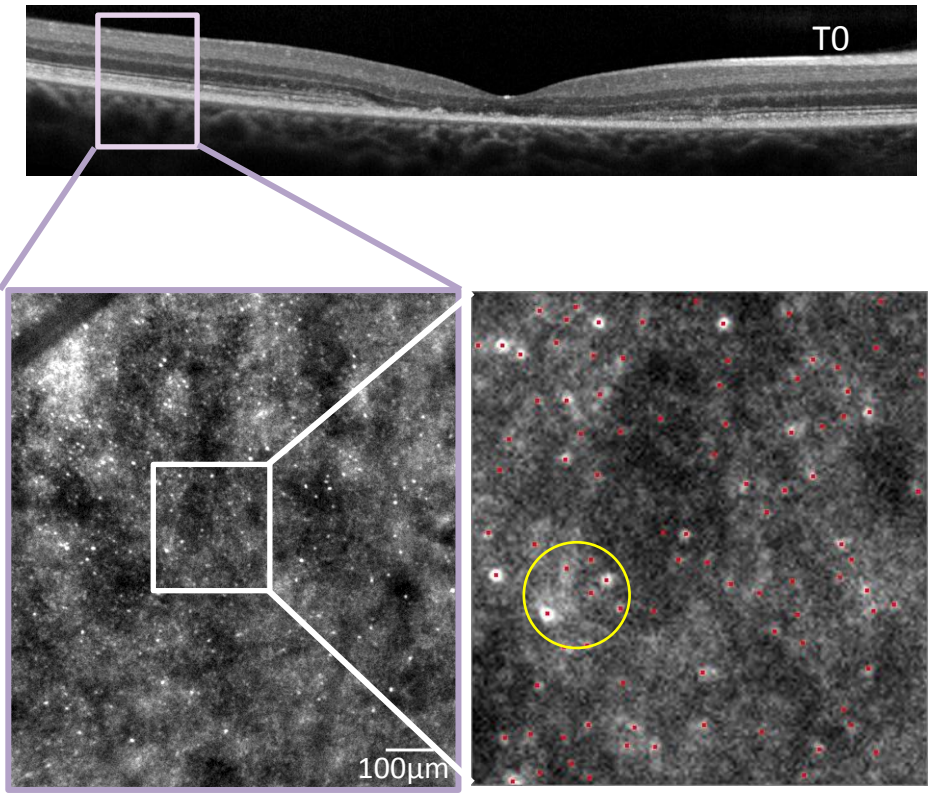

94 cones

Spacing 57µm

T0+12m

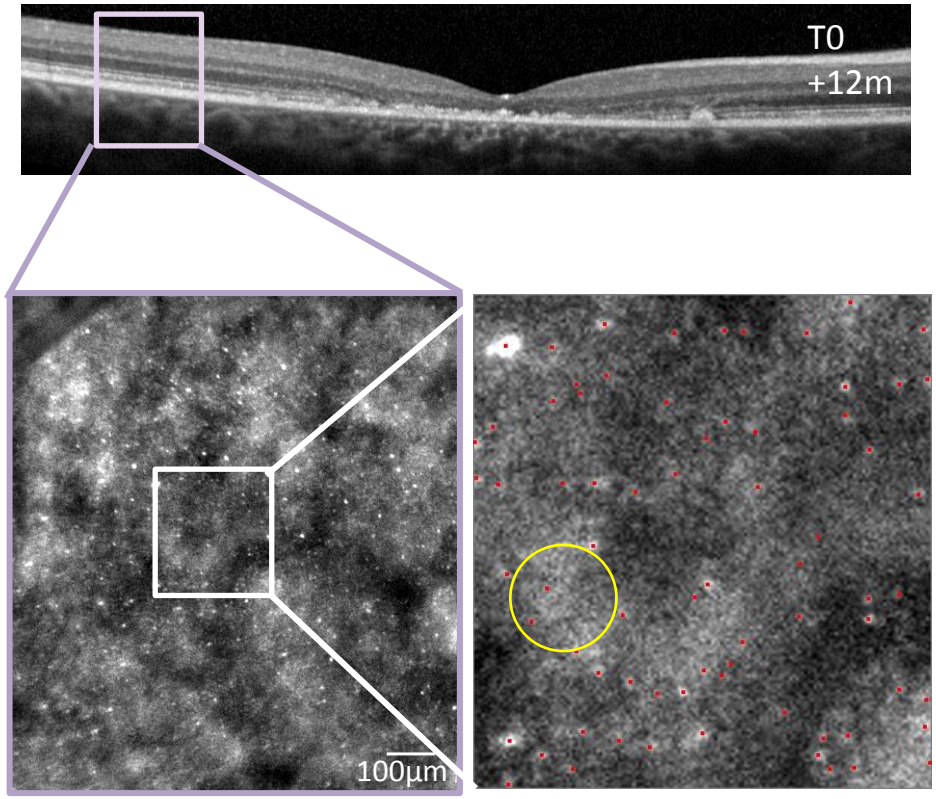

72 cones

Spacing 65µm

imagine eyes

Images : courtesy K. Gocho-Nakashima & M. Paques, Quinze-Vingts National Eye Hospital, Paris
Analysis: courtesy K. Loquin & F. Rossant, ISEP, Paris

Geographic atrophy in **dry AMD**

- The rtx1 can detect atrophic progression **in very short times**
- It provides the **sharpest views** of atrophic area borders
- It reveals the **migration** of numerous pigmented cells, previously unseen

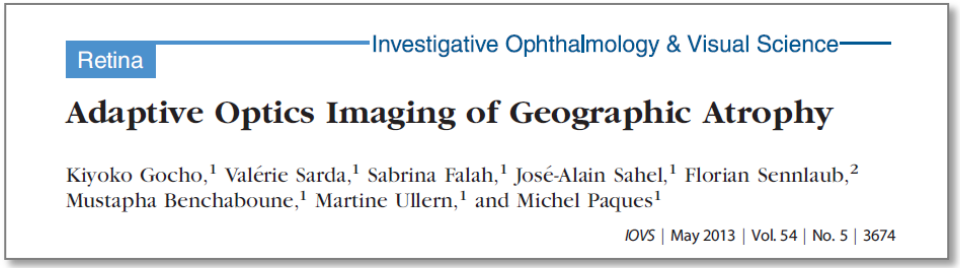
Retina

Investigative Ophthalmology & Visual Science

Adaptive Optics Imaging of Geographic Atrophy

Kiyoko Gocho,[1] Valérie Sarda,[1] Sabrina Falah,[1] José-Alain Sahel,[1] Florian Sennlaub,[2] Mustapha Benchaboune,[1] Martine Ullern,[1] and Michel Paques[1]

IOVS | May 2013 | Vol. 54 | No. 5 | 3674

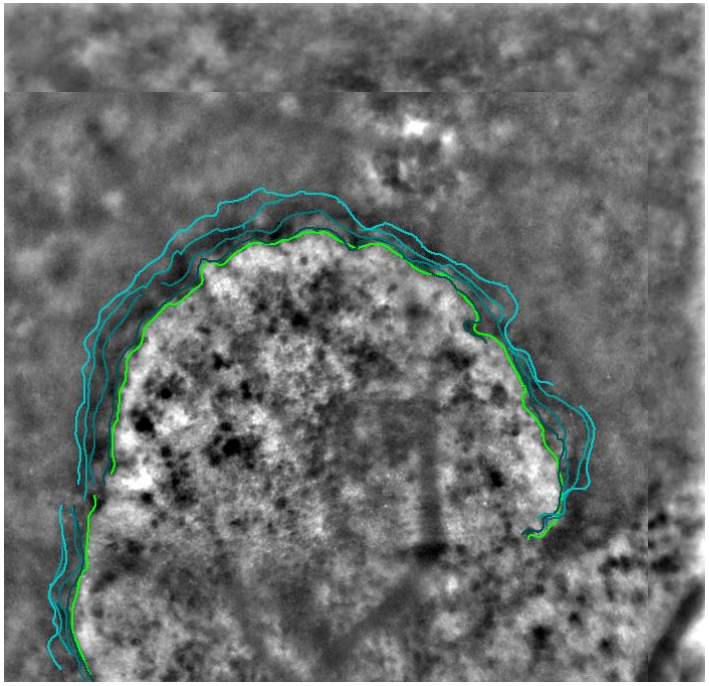

5-month follow-up of an atrophic area

Progression detected in 2 weeks

imagine eyes

Images: courtesy of Gocho, Paques et al., Quinze-Vingts National Eye Hospital, Paris, France

Vitroretinal **surgery** outcome assessment

- The rtx1 enables assessing the **integrity of visual cells** following retinal surgery

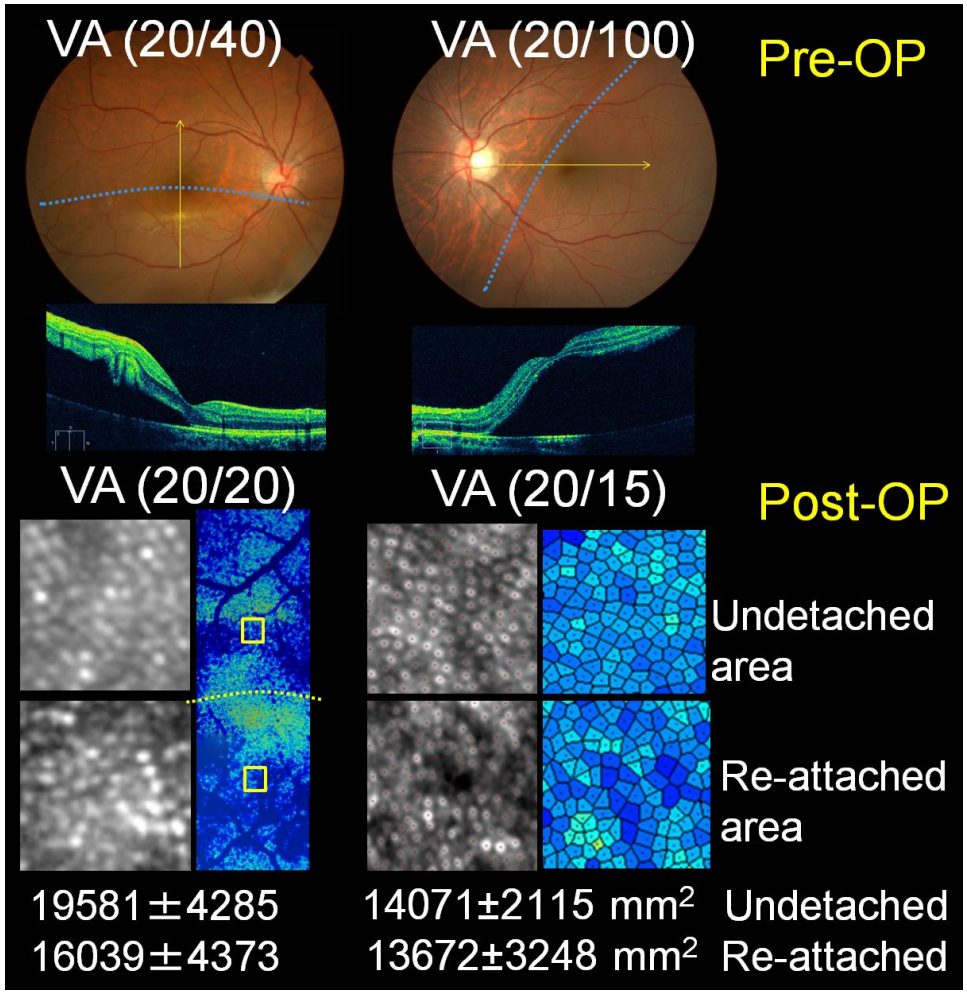

Recovery of the cone cell mosaic in 2 cases of retinal detachment examined 1 year after surgery

imagine eyes

Images: courtesy Kawano, Ito, Terasaki et al., Nagoya University, Japan

Drug **toxicity**

- Highly-sensitive detection of **microscopic alterations** in the retina caused by drug toxicity



Abnomal cone photoreceptor pattern caused by chloroquine toxicity

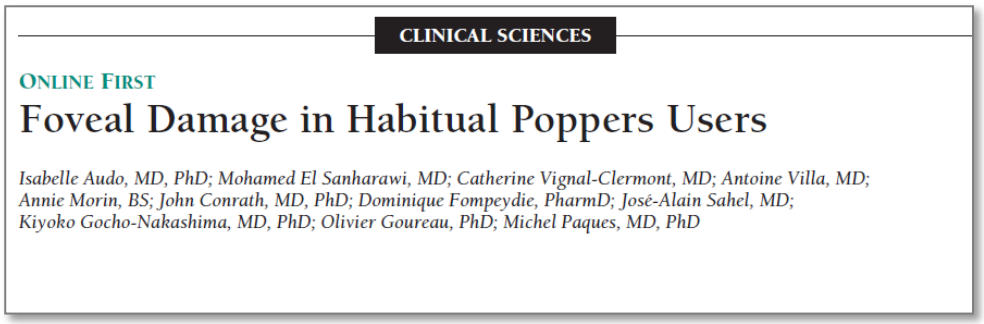

CLINICAL SCIENCES

ONLINE FIRST

Foveal Damage in Habitual Poppers Users

Isabelle Audo, MD, PhD; Mohamed El Sanharawi, MD; Catherine Vignal-Clermont, MD; Antoine Villa, MD; Annie Morin, BS; John Conrath, MD, PhD; Dominique Fompeydie, PharmD; José-Alain Sahel, MD; Kiyoko Gocho-Nakashima, MD, PhD; Olivier Goureau, PhD; Michel Paques, MD, PhD

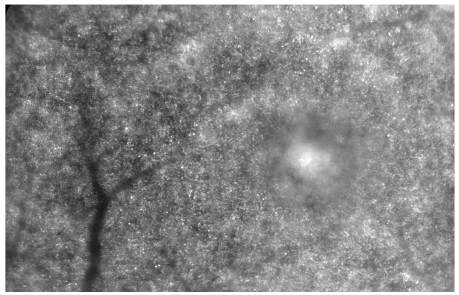

Microscopic retinal lesion caused by recreational 'popper' drugs

imagine eyes

Chloroquine toxicity images: courtesy G. Michelson, Friedrich-Alexander Universität Erlangen, Germany,
Popper toxicity images: courtesy of Audo, Gocho, Paques et al., Quinze-Vingts National Eye Hospital, Paris, France

Foveal damage caused by recreational drugs (« poppers »)

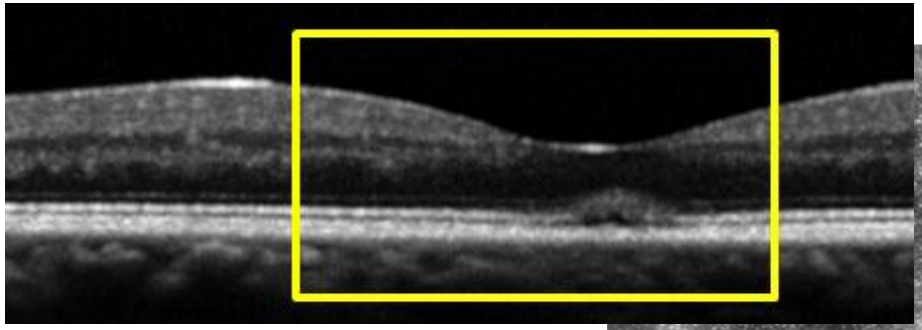

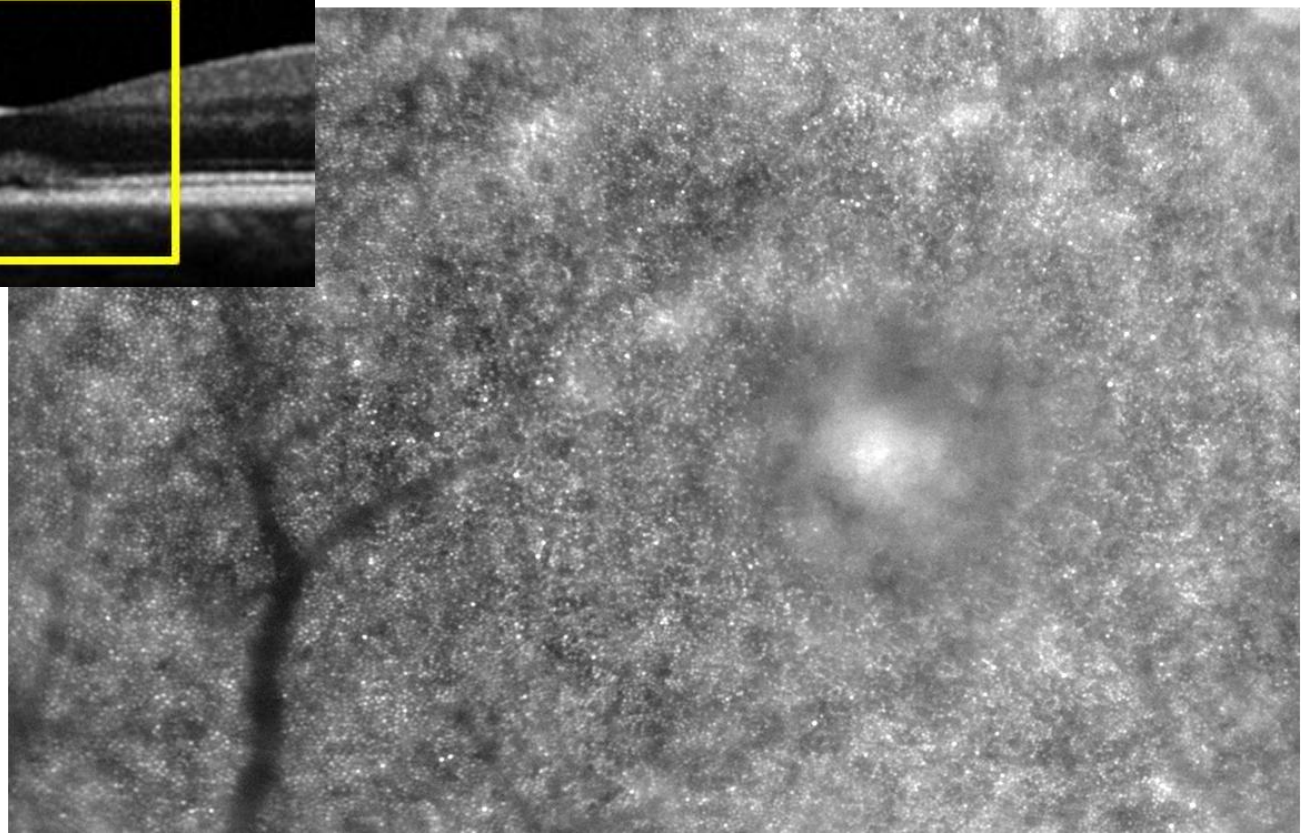

Vignal, Audo, Sahel, Paques, ***New Engl. J. Med. 2010***

imagine eyes

Nivaquine retinopathy

28 y.o. male

imagine eyes

Courtesy K. Gocho-Nakashima & M. Paques, Quinze-Vingts National Eye Hospital, Paris

Nivaquine retinopathy



OD

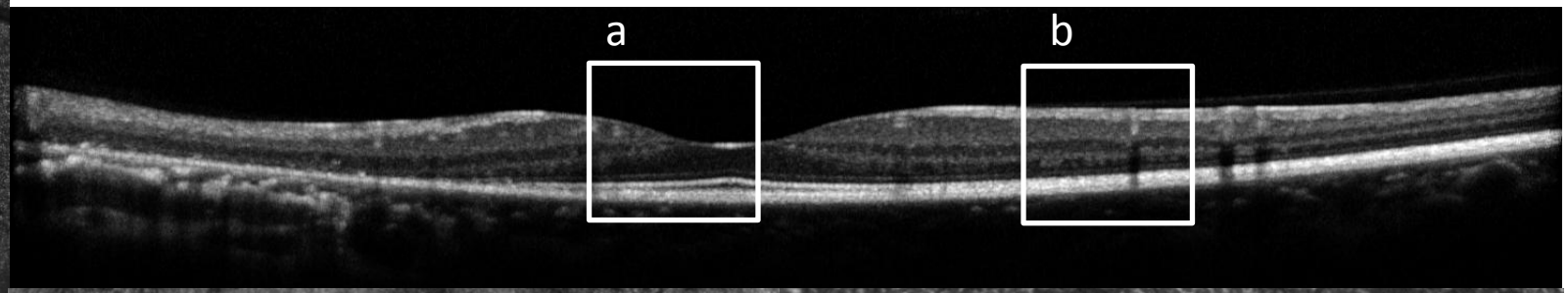

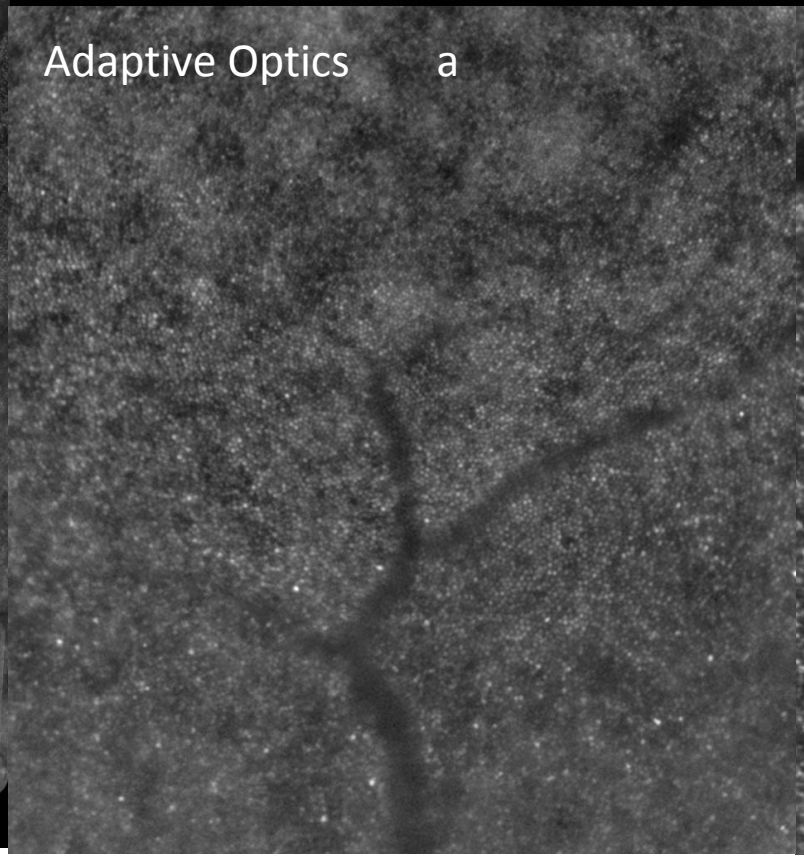

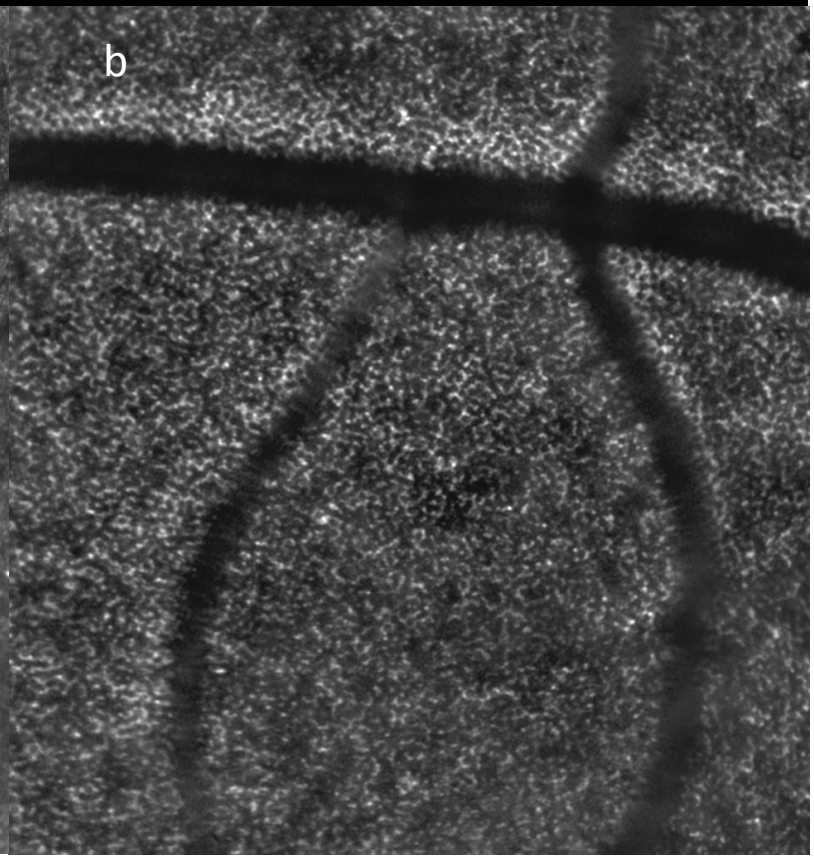

imagine eyes

Courtesy K. Gocho-Nakashima & M. Paques, Quinze-Vingts National Eye Hospital, Paris

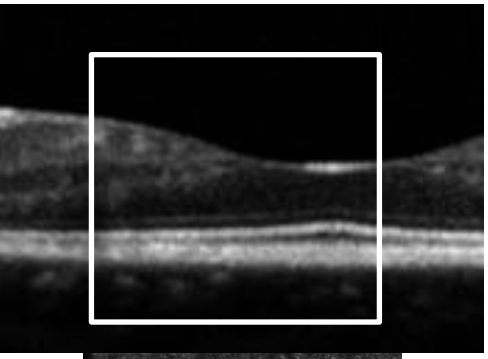

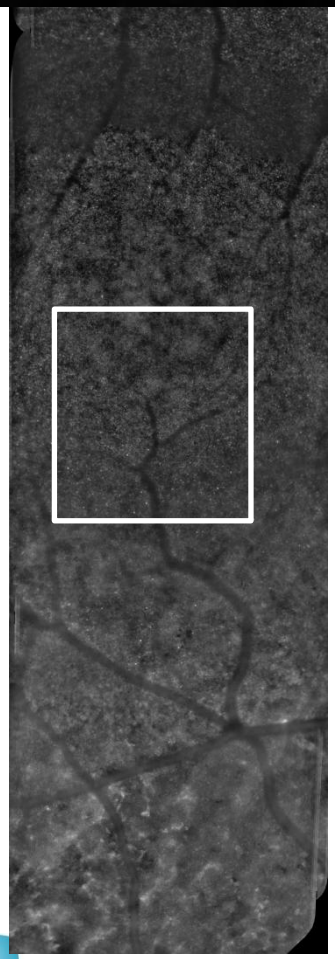

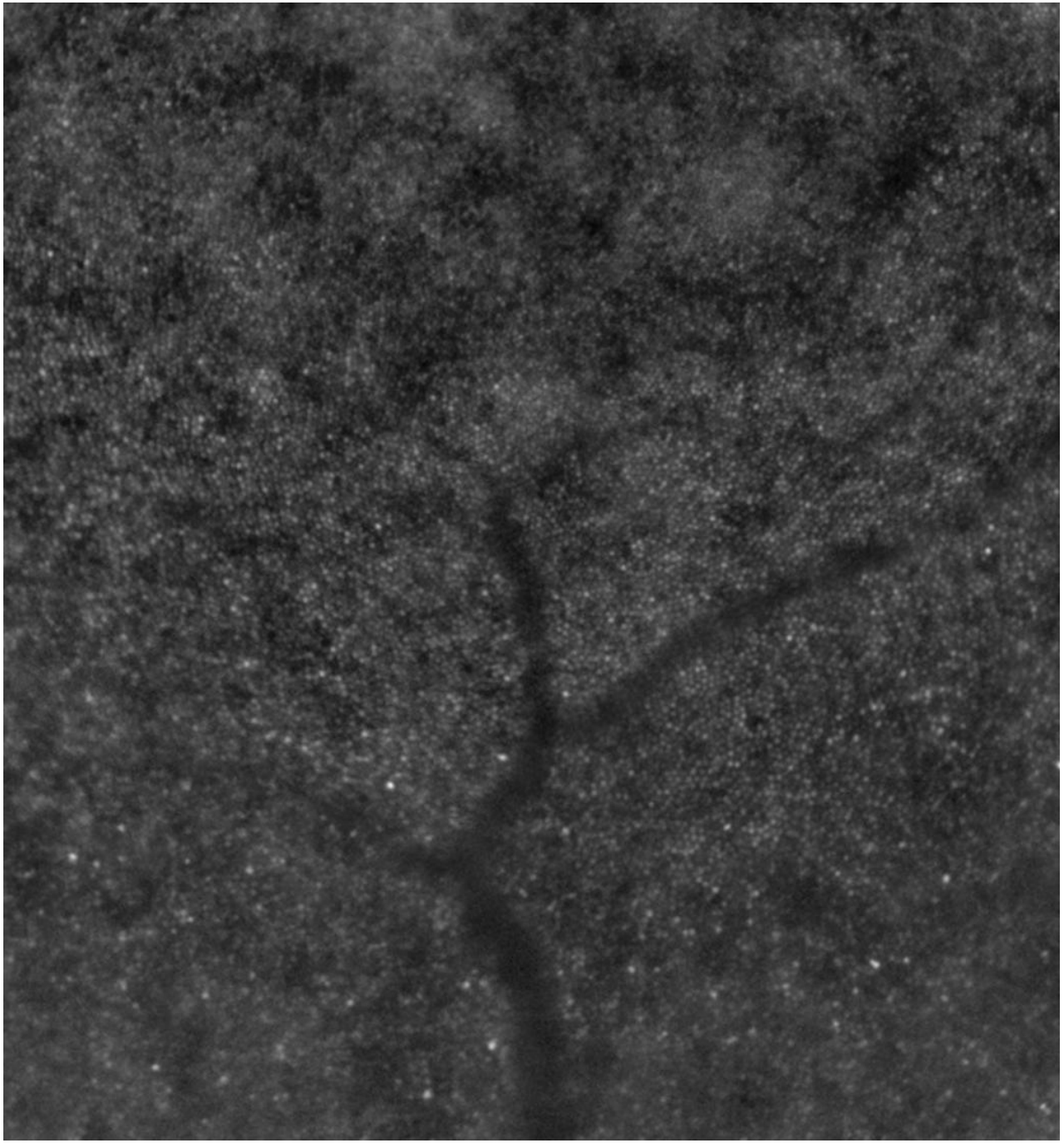

imagine eyes



imagine eyes

Courtesy K. Gocho-Nakashima & M. Paques, Quinze-Vingts National Eye Hospital, Paris

Glaucoma research

- Assessment of **pore elongation** in the lamina cribrosa
- Visualization of losses in **optic nerve fiber bundles** at the border of the papilla
- Observation of patchy losses in cone visibility in photoreceptor images

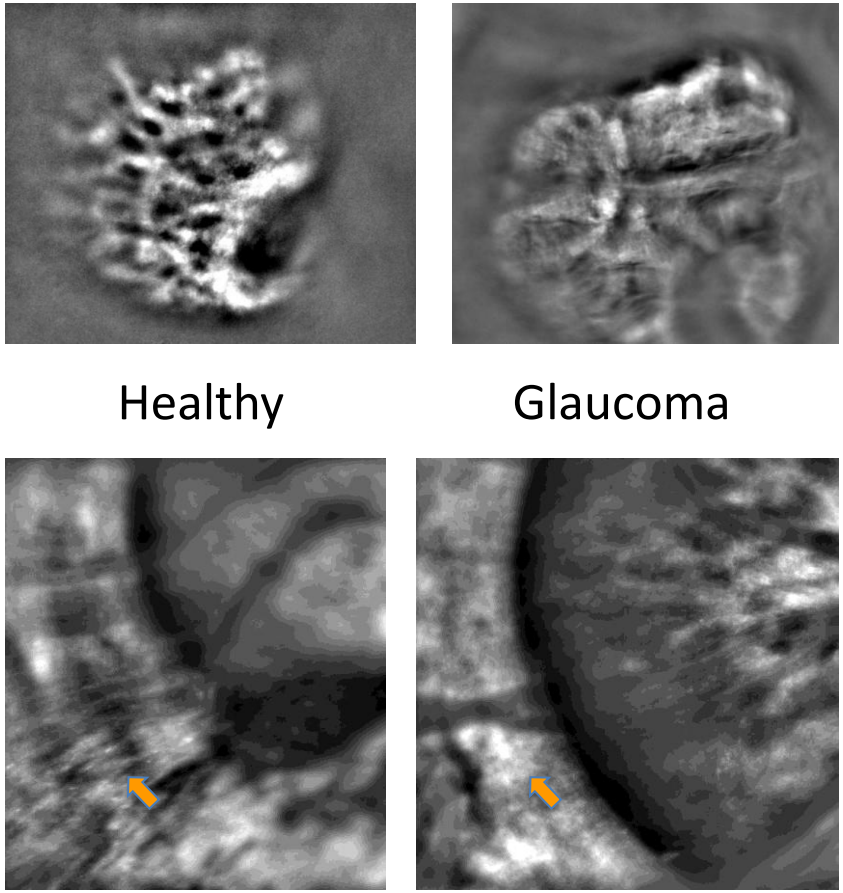

imagine eyes

Images: courtesy of Gocho , Kameya et al., Nippon Medical School Hokusoh Hospital, Chiba, Japan

Diabetes

Non invasive visualization of **early signs** of diabetic retinopathy:

- Micro-hemorrhage
- Microaneurism
- Capillary narrowing

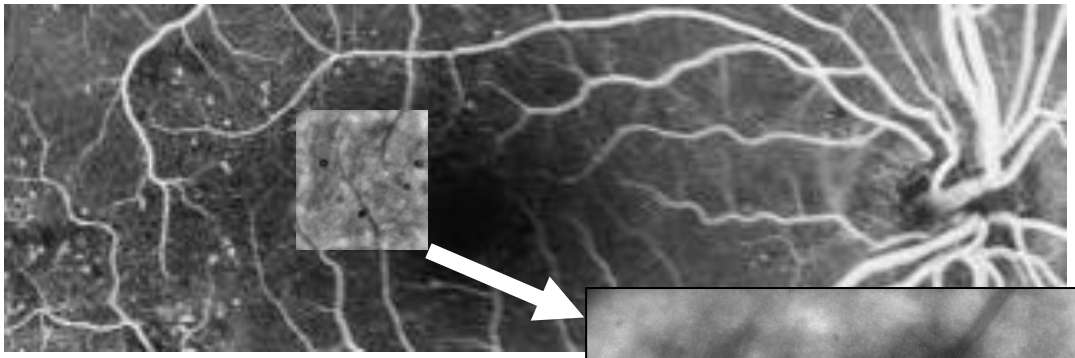

Fluorescein angiography

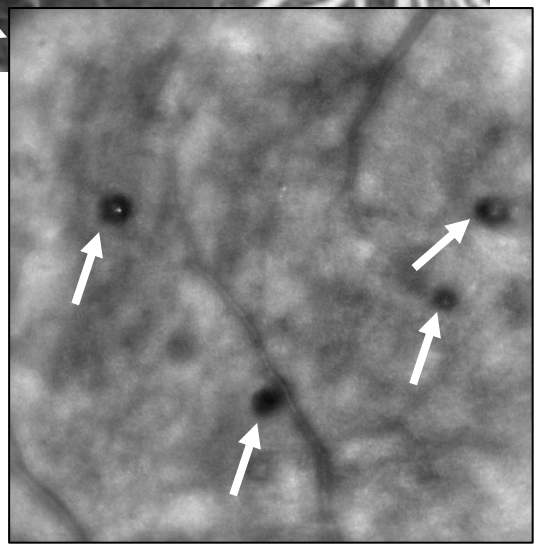

rtx1 image: **microaneurisms**

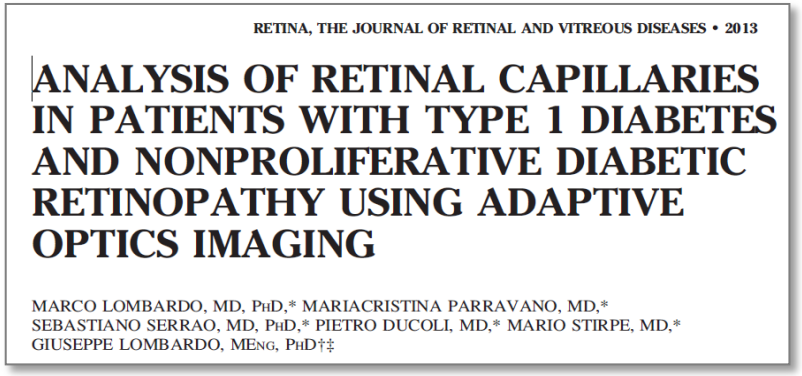

RETINA, THE JOURNAL OF RETINAL AND VITREOUS DISEASES • 2013

ANALYSIS OF RETINAL CAPILLARIES IN PATIENTS WITH TYPE 1 DIABETES AND NONPROLIFERATIVE DIABETIC RETINOPATHY USING ADAPTIVE OPTICS IMAGING

MARCO LOMBARDO, MD, PHD,* MARIACRISTINA PARRAVANO, MD,* SEBASTIANO SERRAO, MD, PHD,* PIETRO DUCOLI, MD,* MARIO STIRPE, MD,* GIUSEPPE LOMBARDO, MENG, PHD†‡

imagine eyes

Images: courtesy of Paques et al., Quinze-Vingts National Eye Hospital, Paris, France

Vascular **inflammation**

- The rtx1 reveals signs of inflammation that are invisible with conventional ophthalmoscopy and FFA:
  - Focal perivascular infiltrates (veinous wall opacifications)
  - Focal lumen narrowings

Retinal vasculitis in a tuberculosis case

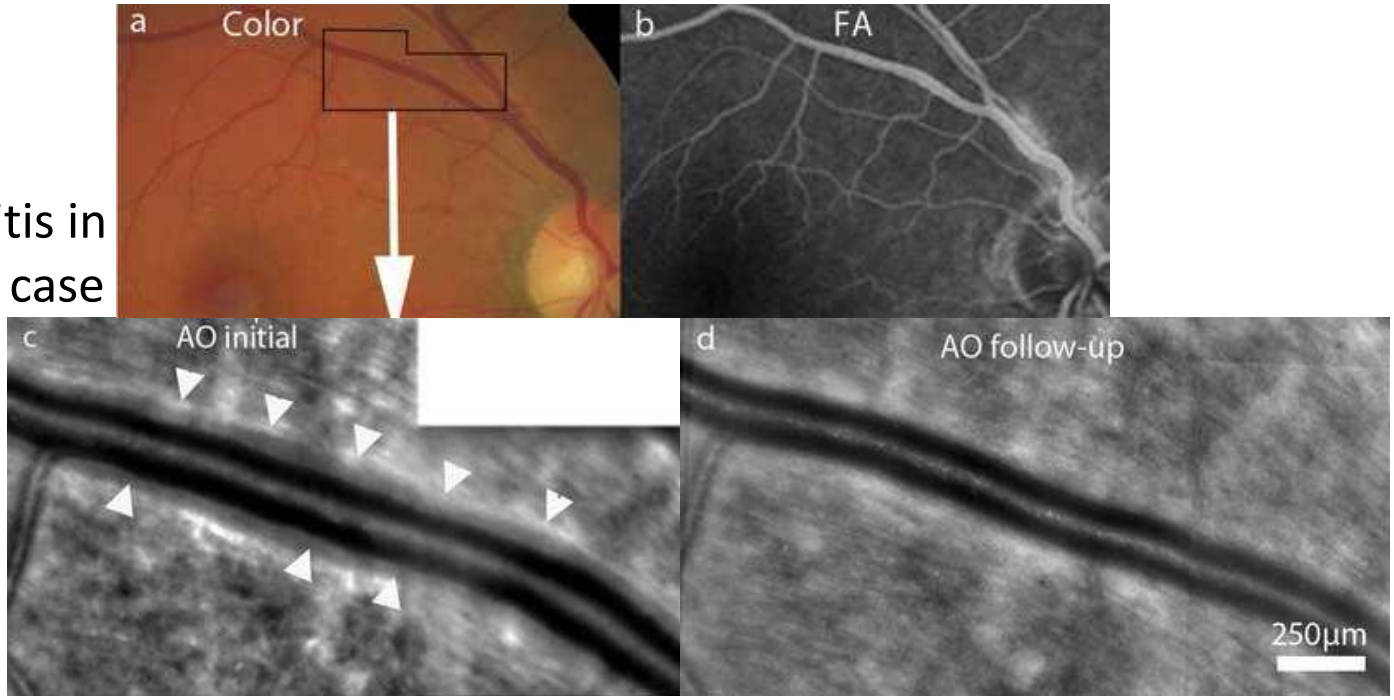

Initial visit: AO images show veinous wall opacification

3 months after initiating treatment: disapearance of infiltrates

imagine eyes

Images: courtesy of Errera, Paques et al., Quinze-Vingts National Eye Hospital, Paris, France

Arterial **hypertension**

- The rtx1 enables non invasive and reproducible assessment of the arteriolar microscopic structure
- The **wall-to-lumen ratio** (WLR) is an exceptional biomarker for arterial hypertension:
  - Early sign of **damage** to small blood vessels
  - Strong **risk** predictor for cardiovascular events

Original Article

Morphometric analysis of small arteries in the human retina using adaptive optics imaging: relationship with blood pressure and focal vascular changes

Edouard Koch[a], David Rosenbaum[b], Aurélie Brolly[a], José-Alain Sahel[a], Philippe Chaumet-Riffaud[a,c], Xavier Girerd[b], Florence Rossant[d], and Michel Paques[a]

Journal of Hypertension 2014, 31:000–000

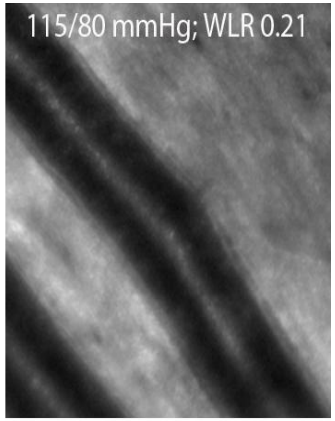

Healthy control
WLR = 0.21



Untreated AHT
WLR = 0.37

imagine eyes

Images: courtesy of Koch, Paques, Girerd et al., Quinze-Vingts National Eye Hospital and Pitie-Salpétrière Hospital, Paris, France

AO imaging of cone outer segment recovery in

MEWDS

(ZESPÓŁ LICZNYCH ZNIKAJĄCYCH BIAŁYCH PUNKTÓW)

Multiple evanescent white dot syndrome (MEWDS)

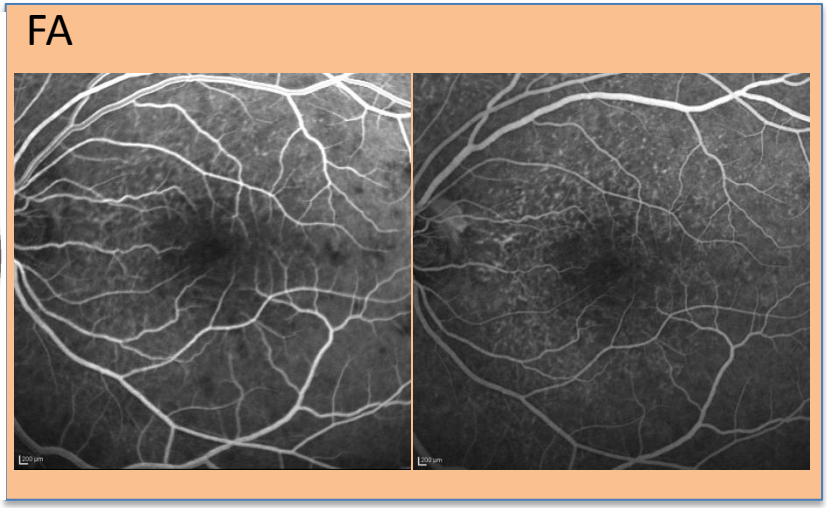

- Unilateral disturbance in visual acuity
- FA: early hyper fluorescence and late staining → damage to RPE
- Late-phase ICGA: hypofluoresent spot → Choroidopathy
- ERG and EOG → dysfunction of photoreceptors and RPE
- SD-OCT : recovering of photoreceptor IS and OS thickness

➢ MEWDS now understood as an outer retinal disease

imagine eyes

Courtesy I. Audo, K. Gocho-Nakashima & M. Paques, Quinze-Vingts National Eye Hospital, Paris

MEWDS#2 OS 4 deg T

T0 VA =20/20 (ETDRS 83)

T0 +1 month VA =20/20 (ETDRS 86)

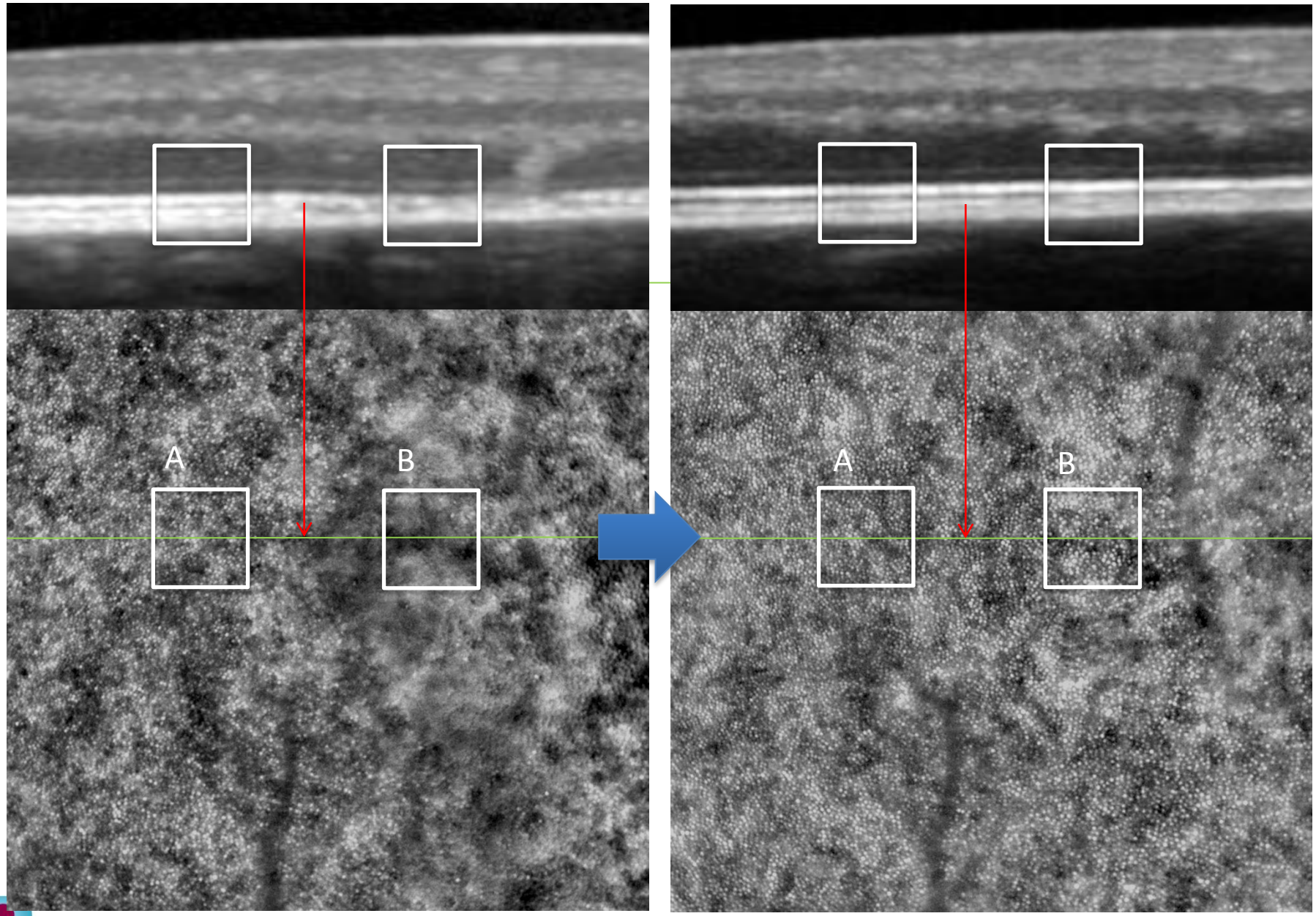

imagine eyes

Courtesy K. Gocho-Nakashima & M. Paques, Quinze-Vingts National Eye Hospital, Paris

MEWDS#2 OS 4 deg T zone A

T0





316 cones

Density: 6507/mm^2

Ratio
1.5 up

T0 + 1 month





466 cones

Density:9596/mm^2

imagine eyes

Courtesy I. Audo, K. Gocho-Nakashima & M. Paques, Quinze-Vingts National Eye Hospital, Paris

MEWDS#2 OS 4 deg T zone B

T0





45 cones

Density: 927 /mm^2

Ratio
7.7 up

T0 + 1 month





348 cones

Density: 7166 /mm^2

imagine eyes

Courtesy I. Audo, K. Gocho-Nakashima & M. Paques, Quinze-Vingts National Eye Hospital, Paris

MEWDS case#1 10-month follow-up

BCVA

20/40

20/20

20/20

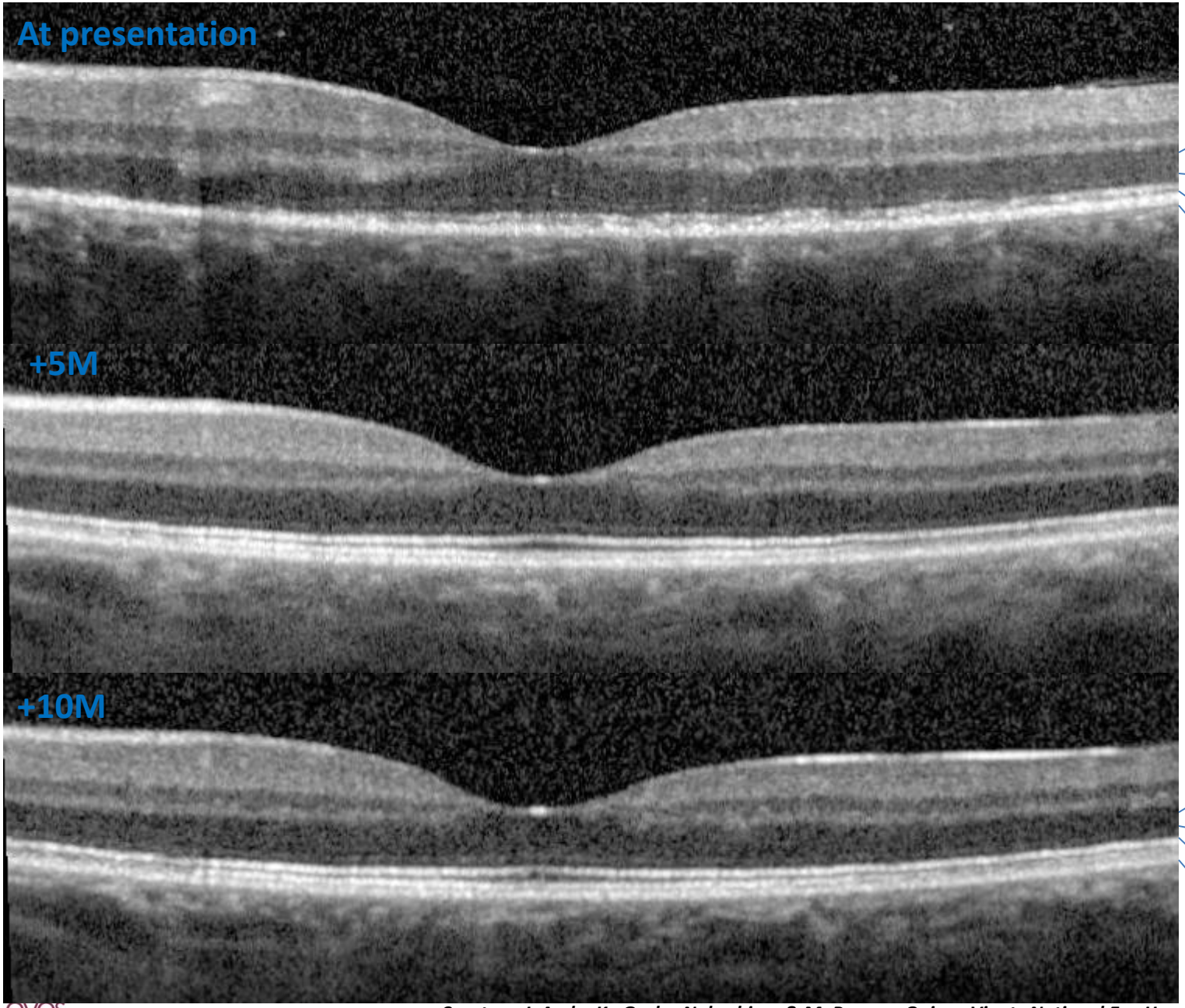

imagine eyes

Courtesy I. Audo, K. Gocho-Nakashima & M. Paques, Quinze-Vingts National Eye Hospital, Paris

MEWDS case#1 10-month follow-up

Presentation



+3 weeks



+2 months



+5 months



+10 months

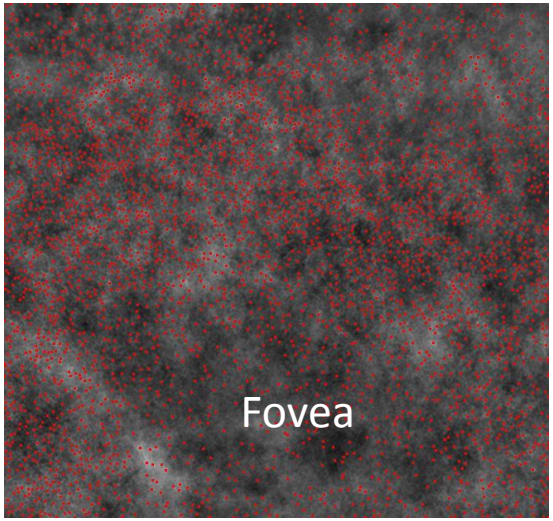

Visite	Cone AO (cones/image)	VA OS
presentation	122	20/40
3 weeks	32	20/20
2 months	1472	20/20
5 months	2359	20/20
10 months	3440	20/20

imagine eyes

Case1 32 y.o. F

Courtesy I. Audo, K. Gocho-Nakashima & M. Paques, Quinze-Vingts National Eye Hospital, Paris

Adaptive optics imaging in

AMNR

ACUTE MACULAR NEURORETINOPATHY

Acute macular neuroretinopathy
One month follow-up

16 y.o., Female

Jan. 13, 2010

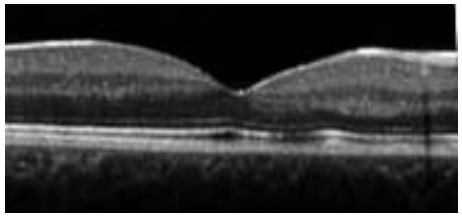



Feb. 16, 2010

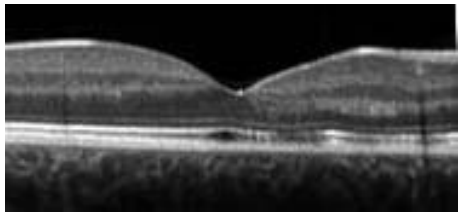

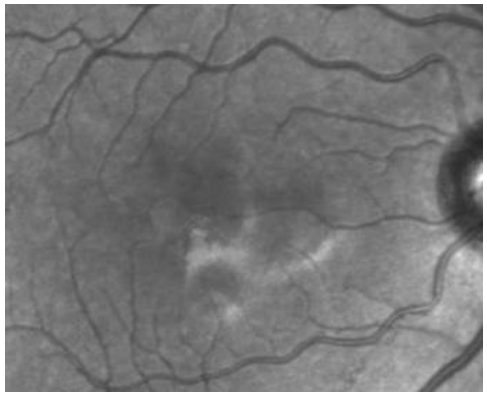



imagine eyes

Courtesy I. Audo, K. Gocho-Nakashima & M. Paques, Quinze-Vingts National Eye Hospital, Paris

Acute macular neuroretinopathy
One month follow-up

16 y.o., Female



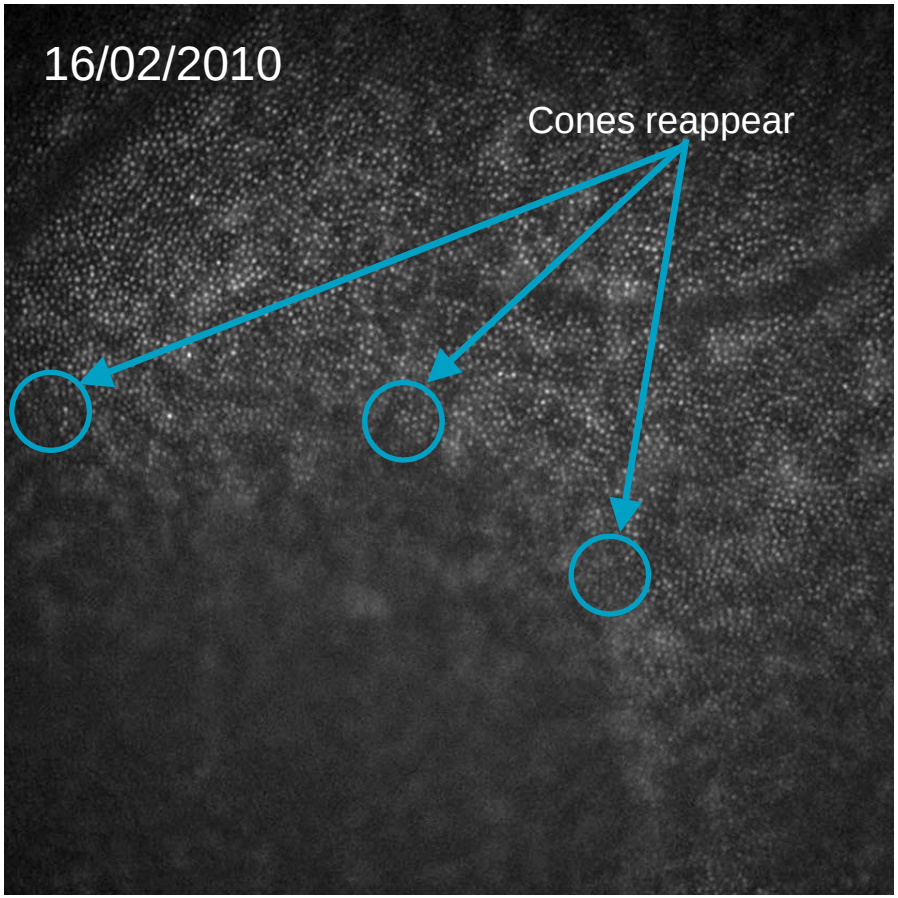

Small changes, invisible using SLO or OCT, are visible using AO

imagine eyes

Courtesy I. Audo, K. Gocho-Nakashima & M. Paques, Quinze-Vingts National Eye Hospital, Paris

THE rtx1'S BREAKTHROUGH TECHNOLOGY

What is **adaptive optics**?

- AO technology was invented by astrophysicists to enhance **image quality** in large ground-based telecopes

Galactic center imaged without AO

Same area imaged using AO

How does adaptive optics work?

- AO uses **deformable mirrors** and **wavefront sensors** to correct distorsions in light waves caused by atmospheric turbulence

Moon surface imaged without AO



Same area imaged using AO

imagine eyes

How does the rtx1 achieve **superior** optical resolution ?

- In every other retinal imaging system, resolution is limited by **distortions in light waves** caused by irregular optical defects in the eye
- The rtx1's adaptive optics **eliminates** these distortions in real time while imaging the retina

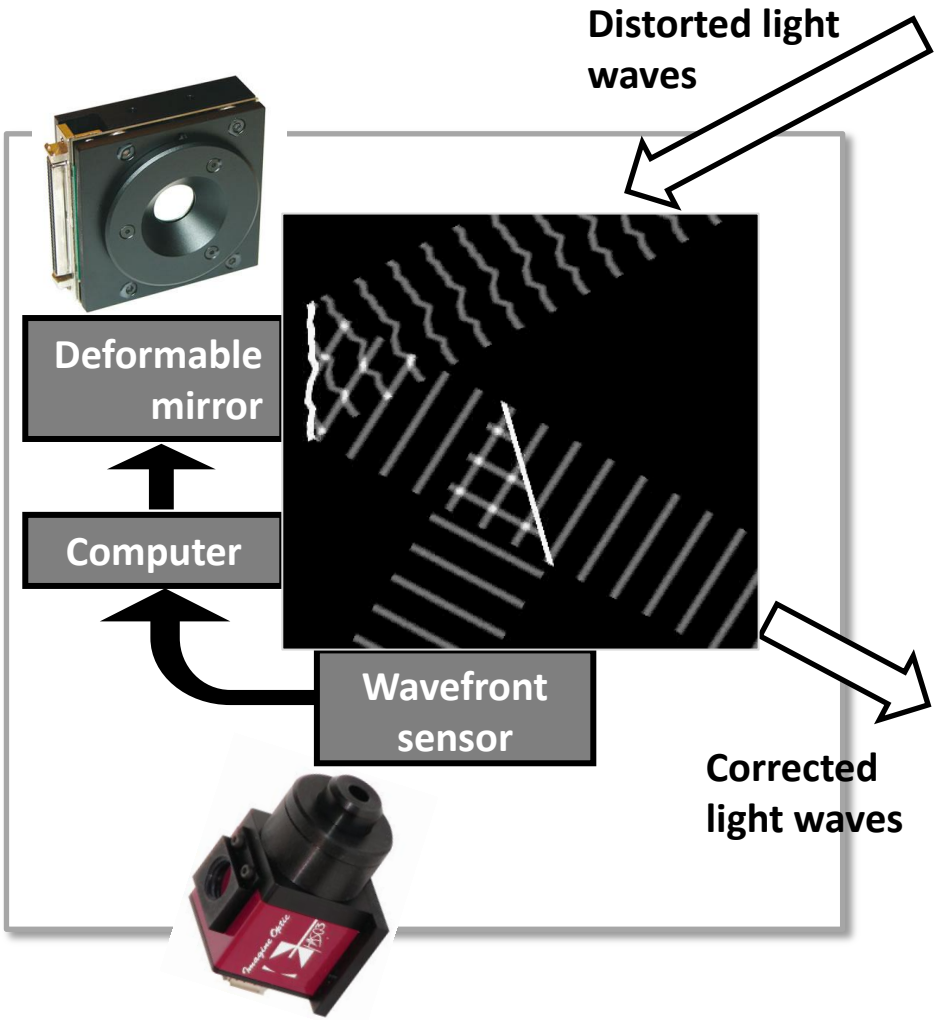

imagine eyes

Thank you

imagine eyes

Adaptive optics

Adapted to ophthalmology